

Follicular Dendritic Cell Sarcoma of the Esophagus - A Case Report

Jong-Hee Nam, Myung-Giun Noh, Na-Ihm Kim, Sung-Sun Kim, Chang-Soo Park, Yoo-Duk Choi*

Department of Pathology, Chonnam National University Medical School, Republic of Korea

*Corresponding author: Yoo-Duk Choi, Department of Pathology, Chonnam National University Medical School, 501-749 Dong-gu, Hak-Dong, 5, Gwangju, Republic of Korea, Fax: +82-62-220-5697; Tel: +82-62-220-5696; E-mail: drydchoi@jnu.ac.kr

Received Date: December 24, 2019 Accepted Date: January 26, 2020 Published Date: January 28, 2020

Citation: Jong-Hee Nam (2020) Follicular Dendritic Cell Sarcoma of the Esophagus - A Case Report. Case Reports: Open Access 5: 1-6.

Abstract

Follicular dendritic cell sarcoma (FDCS) is a rare neoplasm arising from the antigen-presenting cells of the B lymphocytes. Most of these tumors are known to occur in lymph nodes and to affect occasionally extranodal sites. However, FDCS in the gastrointestinal tract has been regarded as an extremely rare neoplasm. Herein, we report a case of primary FDCS originating from the esophagus in a 44-year-old man. The tumor was comprised of the oval to spindle-shaped cells in focal storiform arrangement admixing with lymphocytes. The tumor cells typically expressed positivity in CD21 and CD35.

Keywords: Esophagus; Dendritic cells; Sarcoma

Introduction

Follicular dendritic cells (FDCs) are located primarily in the germinal centers of secondary lymphoid organs and their function is to present antigens to specialized lymphocytes in cooperation with dendritic cells and Langerhans cells. Follicular dendritic cell sarcoma (FDCS) is a rare tumor arising from the antigen-presenting cells of the B-cell follicles of the lymph nodes [1]. Most FDCS arise within the lymph nodes (LNs). The incidence of FDCs is less than 0.1% of all lymphoid malignancy [2]. However, approximately 30% of FDCS have been reported to be located at extranodal sites including the tonsil, oral cavity, gastrointestinal tract, intra-abdominal soft tissue, and breast [3,4,5,6]. FDCS of the gastrointestinal tract is an extremely rare neoplasm with only 20 cases being reported. In the current study, we present our experience of FDCS arising from the esophagus in a 44-year-old man. The diagnosis is confirmed by immunohistochemistry. To our knowledge, ours is the second case of esophageal FDCS reported. Given the rarity of this tumor, additional experiences are needed for the further evaluation of the tumor's clinicopathologic features and the assessment of prognosis should be conferred.

Case report

The patient was a 44-year-old male who presented with foreign body sensation in the throat of a 3-month history. There was no history of vomiting, swallowing difficulty or bleeding in the oral cavity. Any palpable mass was not detected through physical examination. A chest CT scan showed a heterogeneous wall thickening at the distal esophagus. On preoperative endoscopy, the small ulcerative lesion was found in the esophagus and biopsy was diagnosed as squamous cell carcinoma (SQC). The patient was performed with Ivor-Lewis operation under general anesthesia for tumor removal.

On gross examination of the resected surgical specimen, two lesions were detected. An ulcerative lesion sized 3.5x1.8 cm was found 5cm away from the gastroesophageal junction. Another lesion found in the submucosal area sized 1.3x1.2 cm was located 6.5cm away from the gastroesophageal junction. (Figure 1a) Histopathological examination of the ulcerative lesion showed prominent keratinization, squamous epithelial dysplasia with invasion. And its final diagnosis was invasive SQC. A preoperative endoscopic biopsy was obtained from the ulcerative lesion. However, the submucosal lesion showed the histological difference from the ulceration. The tumor showed a well-circumscribed nodular architecture pattern and composed

of interlacing fascicles of the short spindle to ovoid cells with vague storiform arrangement. The tumor cells were round, oval or spindle-shaped and elongated, plump nuclei admixed with mature lymphocytes. It also showed unequivocal nuclear atypism, indistinct cell border with a high mitotic figure representing more than 30 per 10 high power fields (HPFs). An area of necrosis was also observed, which was prominent within the center of the tumor. (Figure 1b,c) On immunohistochemistry, tumor cells exhibited the positive reactivity for CD21, CD35, and vimentin. (Figure 1d) The expression of CK, EBV, C-kit, CD31, S-100, P63, actin and ALK was not found. Consequently, the diagnosis was made as follicular dendritic cell sarcoma. After the pathologic diagnosis was made, a PET/CT scan was performed. It revealed no hypermetabolic lesion at anastomotic site and lymph nodes. After the operation, the foreign body sensation symptom was disappeared from the patients, but, the patient refused an additional chemo-radiation therapy and have not visited the hospital so far.

Discussion

FDCs present antigens to the B lymphocytes forming the network in the germinal centers of the lymph nodes [7]. The neoplasm derived from these cells are called FDCS which is very uncommon. Monda et al [8]. first described FDCS and Chan et al [3]. reported the first extranodal tumor. To date, less than 350 cases were reported [9].

Most of FDCS are found in LNs, often involved in cervical LNs and occasionally in axillary and mediastinal LNs. One-third of cases were found in extranodal sites including tonsil, nasopharynx, liver, spleen and gastrointestinal tract. Since most of extranodal FDCS revealed a predilection for head and neck regions, [10] gastrointestinal FDCS were relatively rare. Only 19 cases including esophagus ($n = 1$), stomach ($n = 5$), colon and rectum ($n = 6$), appendix ($n = 2$), and small intestine ($n = 5$) were reported [4,11,12,13,14,15,16].

So far, one case of esophageal follicular dendritic cell sarcoma has been reported [11]. The tumor was removed by endoscopic submucosal dissection. The patient initially refused additional chemoradiation therapy. After two years, the tumor recurred and later treated, but died during treatment. The case showed an aggressive clinical course. So it is believed that additional chemoradiation therapy will be needed after the surgery. Unfortunately, our case is not known about the patient's clinical course after the surgery, it is difficult to include additional information on esophageal FDCS.

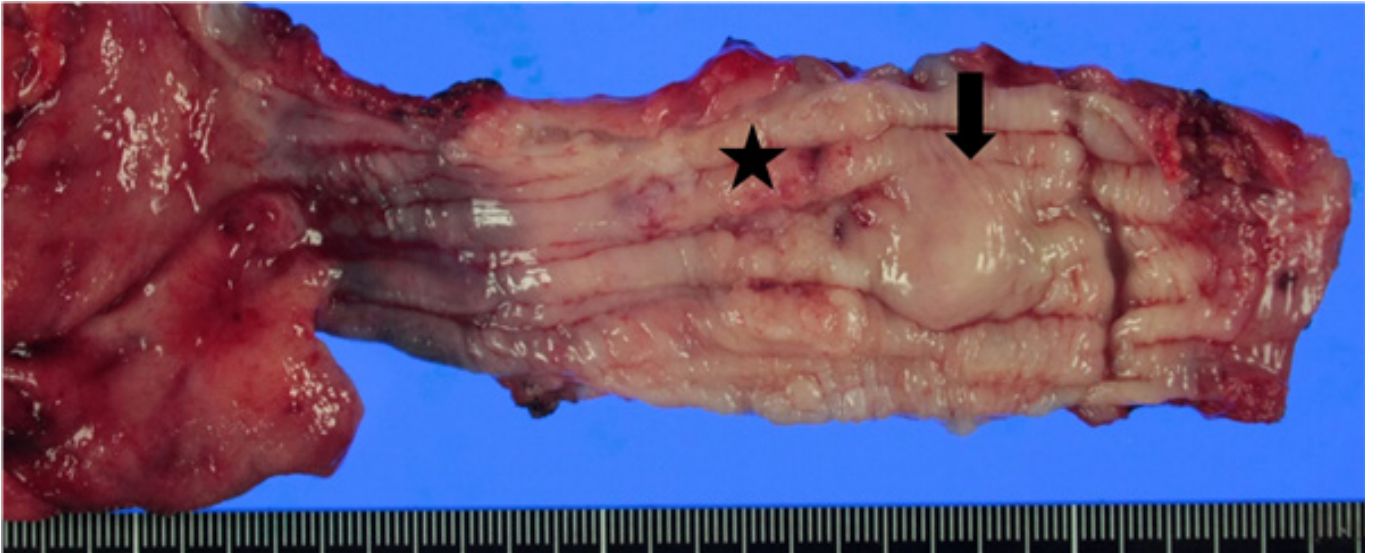


Figure.1a. An ulcerative lesion (asterisk) is found at 5cm away from the gastroesophageal junction. Submucosal lesion (arrow) is located 6.5cm away from the gastroesophageal junction.

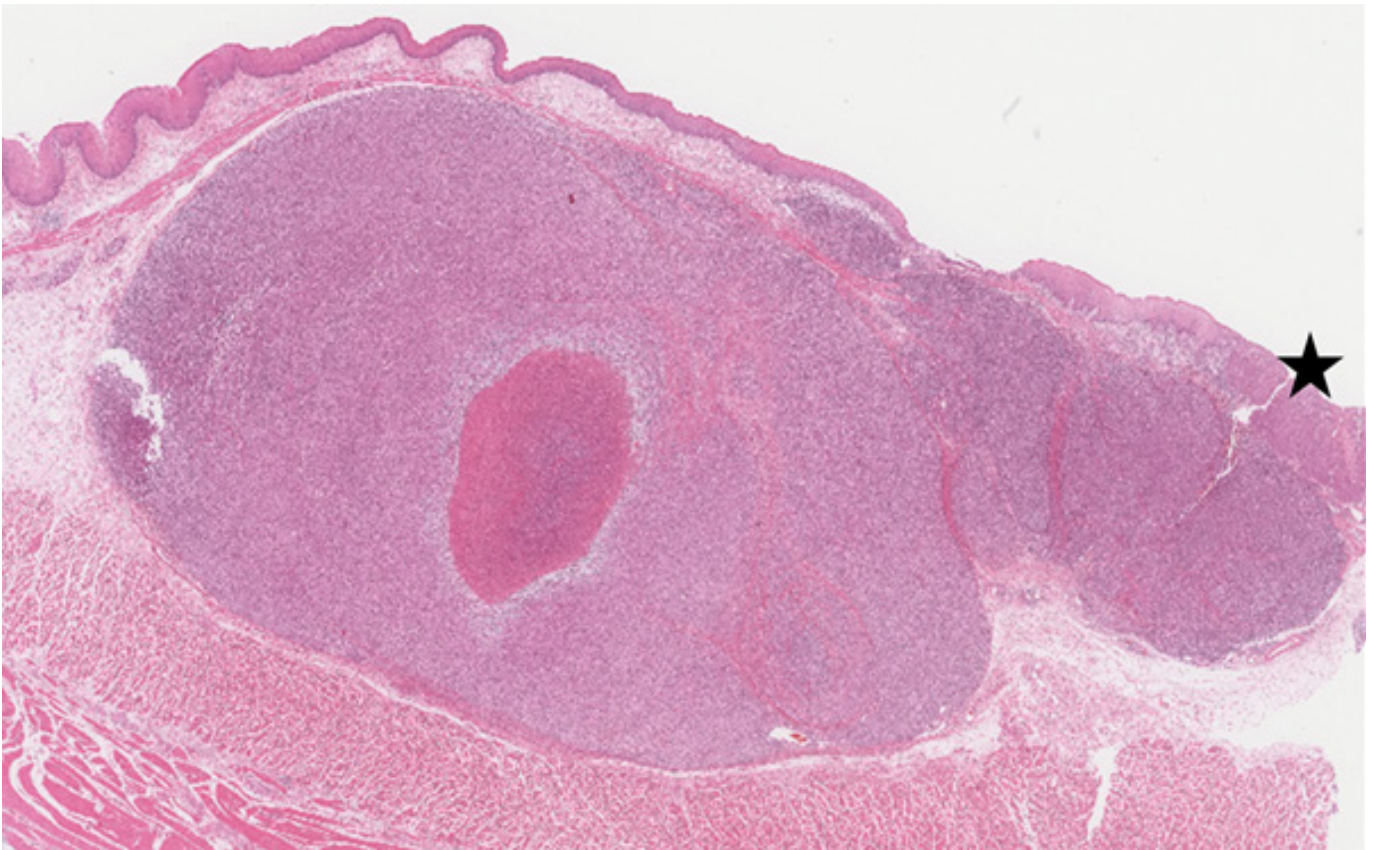


Figure.1b. The submucosal lesion is a relatively well-demarcated nodular pattern with central necrosis. Squamous carcinoma is also seen (asterisk). (H&E, X10)

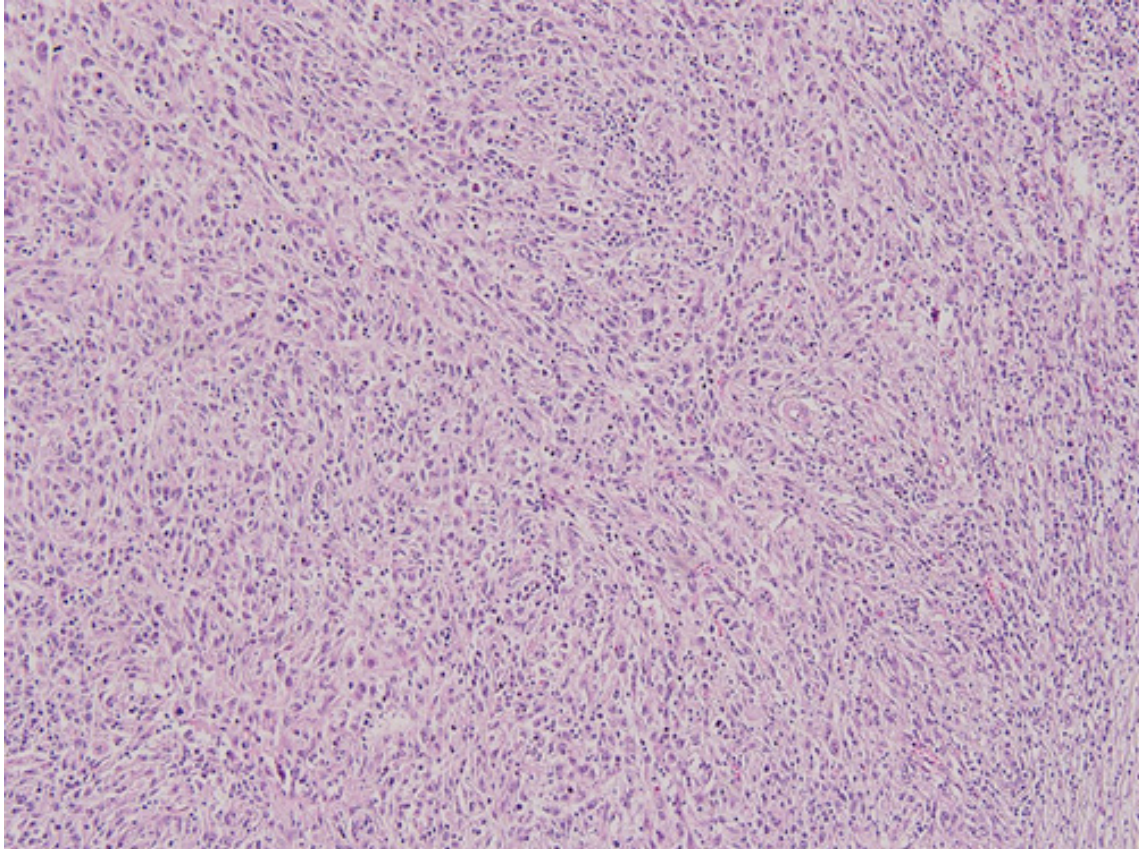


Figure.1c. The submucosal tumor is composed of interlacing fascicles of the short spindle to ovoid cells with vague storiform arrangement. The tumor cells show unequivocal nuclear atypism, prominent nucleoli, indistinct cell border, and a high mitotic figure representing more than 30 per 10 high power fields (HPFs). (H&E, X100)

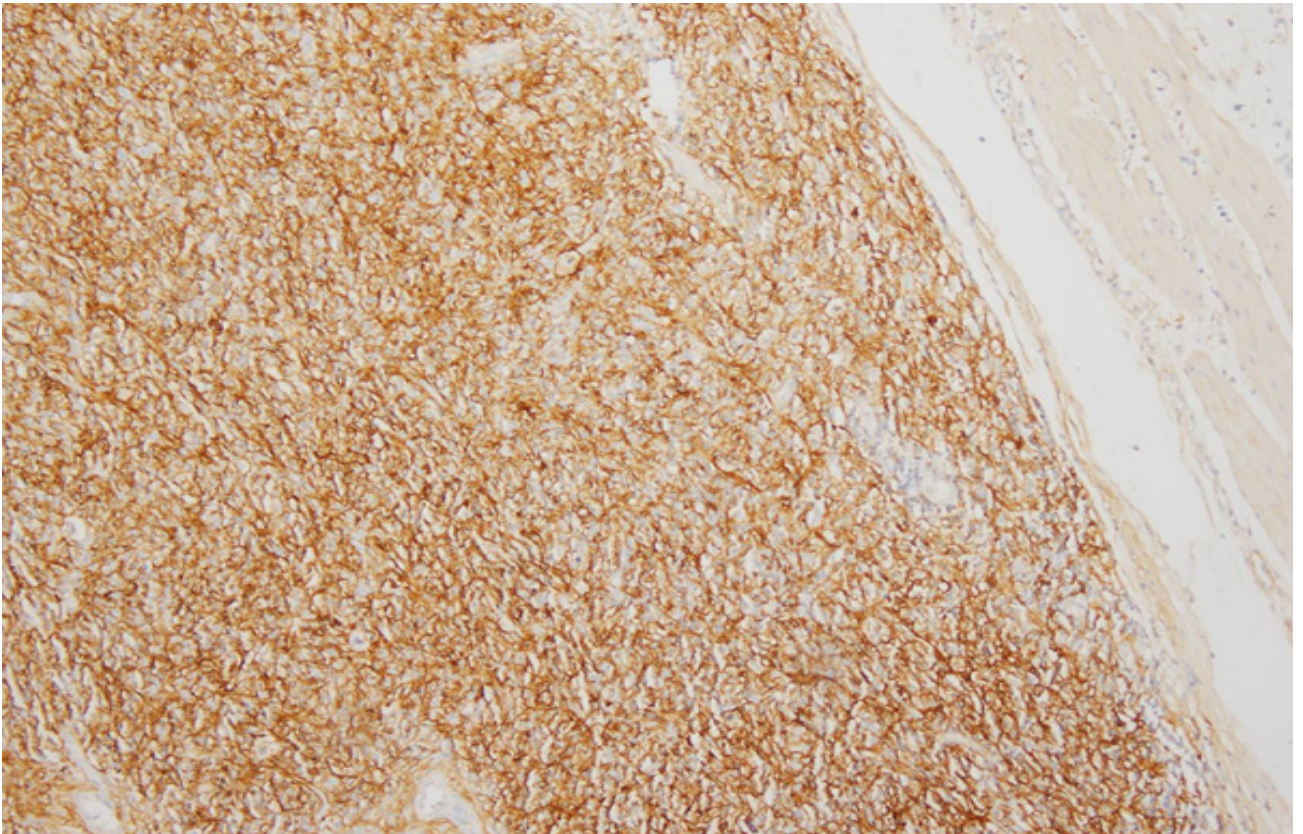


Figure.1d. The tumor cells show a strong immunoreactive for CD21. (X100)

The pathological diagnosis of gastrointestinal FDCs can be challenging due to the histologic resemblances to other tumors in the gastrointestinal tract [10]. The differential diagnosis would include gastrointestinal stromal tumors (GIST), fibrohistiocytic tumors, and undifferentiated spindle cell tumors. For the diagnosis of this tumor, a combination of morphological, immunohistochemical, and electron microscopic analyses is required. If the tumor exhibits fascicles or storiform arrangement of spindle-shaped cells, indistinct cell borders and background of lymphocytes scattered throughout the neoplastic cells, FDCS should be also considered. The microscopic findings of our case were typical of FDCS with histologic findings shown above, although previous studies have reported a broad spectrum of morphologic variation, and an atypical features in the form of a multifocal involvement and giant cell transformation. To confirm the diagnosis, immunohistochemistry was applied. FDCS typically shows positive for one or more of the follicular dendritic markers, such as CD21 and CD35.

FDCS has been considered as an intermediate-grade soft tissue sarcoma but clinical behaviors are diverse. Various treatment modalities have been used for the treatment of this tumor including surgical resection, chemotherapy and radiation therapy. Complete surgical resection is preferred as treatment of choice. Yet, there is no consensus established on optimal and adjuvant chemotherapy. Adjuvant radiotherapy or chemotherapy can be applied for recurrence, incomplete resection of the tumor and high-risk patients who are unsuitable for surgery. Cases with significant cytological atypia, extensive coagulative necrosis, mitotic count of $>5/10$ HPFs, or tumor size greater than 6 cm showed a poor prognosis, whereas lesions arising in the lymph nodes behave as low-grade sarcoma with a relatively good prognosis [17]. No definite therapeutic approaches have demonstrated consistent efficacy [9].

Conclusion

I report the second case of primary FDCS originating in the esophagus.

References

1. Fonseca R, Yamakawa M, Nakamura S, van Heerde P, Miittinen M, Shek TW, et al. (1998) Follicular dendritic cell sarcoma and interdigitating reticulum cell sarcoma: a review. *Am J Hematol* 59: 161-167.
2. Perez-Ordóñez B, Erlandson RA, Rosai J (1996) Follicular dendritic cell tumor: report of 13 additional cases of a distinctive entity. *Am J Surg Pathol* 20: 944-955.
3. Aydin E, Ozluoglu LN, Demirhan B, Arıkan U (2006) Follicular dendritic cell sarcoma of the tonsil: case report. *Eur Arch Otorhinolaryngol* 263: 1155-1157.
4. Chan JK, Tsang WY, Ng CS, Tang SK, Yu HC, Lee AW (1994) Follicular dendritic cell tumors of the oral cavity. *Am J Surg Pathol* 18: 148-157.
5. Hollowood K, Stamp G, Zouvani I, Fletcher CD (1995) Extranodal follicular dendritic cell sarcoma of the gastrointestinal tract: morphologic, immunohistochemical and ultrastructural analysis of two cases. *Am J Clin Pathol* 103: 90-97.
6. Kapucuoglu N, Percinel S, Ventura T, Lang R, Al-Daraji W, Eusebi V (2009) Dendritic cell sarcomas/tumors of the breast: report of two cases. *Virchows Arch* 454: 333-339.
7. Malik A, Veniyoor A, Fanthome B, Dutta V (2012) Follicular dendritic cell sarcoma: A diagnostic challenge!. *J Cancer Res Ther* 8: 306-307.
8. Monda L, Warnke R, Rosai J (1986) A primary lymph node malignancy with features suggestive of dendritic reticulum cell differentiation. A report of 4 cases. *Am J Pathol* 122: 562-572.
9. Saygin C, Uzunaslan D, Ozguroglu M, Senocak M, Tuzuner N (2013) Dendritic cell sarcoma: a pooled analysis including 462 cases with the presentation of our case series. *Crit Rev Oncol Hematol* 88: 253-271.
10. Duan GJ, Wu F, Zhu J, Guo DY, Zhang R, Shen LL, et al. (2010) Extranodal follicular dendritic cell sarcoma of the pharyngeal region: a potential diagnostic pitfall, with literature review. *Am J Clin Pathol* 133: 49-58.
11. Ren W, Sun Q, Wu PY, Huang B, Yang J, Yan J, et al. (2018) Profiles of genomic alterations in primary esophageal follicular dendritic cell sarcoma: A case report. *Medicine (Baltimore)* 97: e13413.
12. Chang KC, Jin YT, Chen FF, Su IJ (2001) Follicular dendritic cell sarcoma of the colon mimicking stromal tumor. *Histopathology* 38: 25-29.
13. Shen DP, Ni XZ, Yin XL, Wu ZY (2009) Clinical and pathological features of follicular dendritic cell sarcoma of the appendix: a case report. *Chin Med J* 122: 1595-1597.
14. Yamada Y, Haga H, Hernandez M, Kubota KC, Orii F, Nagashima K, et al. (2009) Follicular dendritic cell sarcoma of small intestine with aberrant T-cell marker expression. *Pathol Int* 59: 809-812.
15. Pan ST, Cheng CY, Lee NS, Liang PI, Chuang SS (2014) Follicular Dendritic Cell Sarcoma of the Inflammatory Pseudotumor-like Variant Presenting as a Colonic Polyp. *Korean J Pathol* 48: 140-145.
16. Shaw D, Cuisson R, Ito H (2014) Follicular dendritic cell sarcoma of the stomach: case report and review of the literature. *Curr Oncol* 21: e775-778.
17. Li L (2010) Clinicopathological features and prognosis assessment of extranodal follicular dendritic cell sarcoma. *World J Gastroenterol* 16: 2504-2519.

Submit your manuscript to a JScholar journal and benefit from:

- ¶ Convenient online submission
- ¶ Rigorous peer review
- ¶ Immediate publication on acceptance
- ¶ Open access: articles freely available online
- ¶ High visibility within the field
- ¶ Better discount for your subsequent articles

Submit your manuscript at
<http://www.jscholaronline.org/submit-manuscript.php>