

## Pleomorphic Rhabdomyosarcoma in Adult: A Very Uncommon Occipital Location

Bouchra Dani\*, Zahra Sayad and Malik Boulaadas

Maxillofacial surgery and stomatology department, IBN SINA University hospital, Rabat, Morocco

\*Corresponding author: Bouchra Dani, Maxillofacial surgery and stomatology department, IBN SINA University hospital, Rabat, Morocco, Tel: 00212662361683, E-mail: bouchradani89@gmail.com

Received Date: December 14, 2020 Accepted Date: January 14, 2021 Published Date: January 16, 2021

Citation: Bouchra Dani (2021) Pleomorphic Rhabdomyosarcoma in Adult: A Very Uncommon Occipital Location. Case Reports: Open Access 6: 1-4.

### Abstract

Rhabdomyosarcoma is a common tumor in children with all its types (pleomorphic, embryonal, alveolar and spindle cell rhabdomyosarcoma). However, it is a very rare tumor in adults, the common type is the pleomorphic rhabdomyosarcoma but it is very rare in the head and neck region.

The diagnosis of the pleomorphic RMS is made by the histopathologic study, this shows the interest of a biopsy before the surgical procedure. The treatment of patients with malignant mesenchymal tumors of the head and neck region is multidisciplinary (radical surgery with postoperative radiotherapy and or chemotherapy) with poor prognosis.

**Keywords:** Pleomorphic Rhabdomyosarcoma; Adult; Occipital Region

## Introduction

Rhabdomyosarcoma is one of the most common tumors of childhood and adolescence, (more than 50% of soft tissue sarcomas) [1]. However, it is a very rare tumor in adults (less than 3% of adult soft tissue sarcomas) [2]. There are four major categories of rhabdomyosarcoma, which include pleomorphic, embryonal, alveolar and spindle cell rhabdomyosarcoma [3]. The pleomorphic form is the most frequent in adults but the neck localization is the rarest. To our knowledge, there are no previous case reports of adult pleomorphic rhabdomyosarcoma occurring in the occipital region in the literature. In this article we will report an uncommon case of pleomorphic rhabdomyosarcoma occurring in the occipital region.

## Case Report

A 72-year-old male patient with no medical history of surgery or trauma, was referred to our department for a huge occipital mass (Figure 1) evolving over 10 months and gradually increasing in volume. The clinical examination found an occipital swelling overflowing on the neck without any inflammatory signs in the skin, the tumor was firm on palpation, painless, well limited, about 8 cm major axis. Examination of cervical lymph nodes showed no palpable lymphadenopathy. The rest of the maxillo-facial, neurological and somatic examination were without particularities. A cranio-facial CT scan (Figure 2) showed the presence of a left-sided, heterogeneous occipital tissue overflowing on the nuchal region, containing areas of central necrosis, measuring 59mm x 73mm x 92mm, that enhanced after contrast injection. The mass was interposed between the spinous muscle and the levator scapulae muscle. The tumor does not infiltrate the skin from which it is separated by subcutaneous fat. The CT scan showed no lymphadenopathy associated.

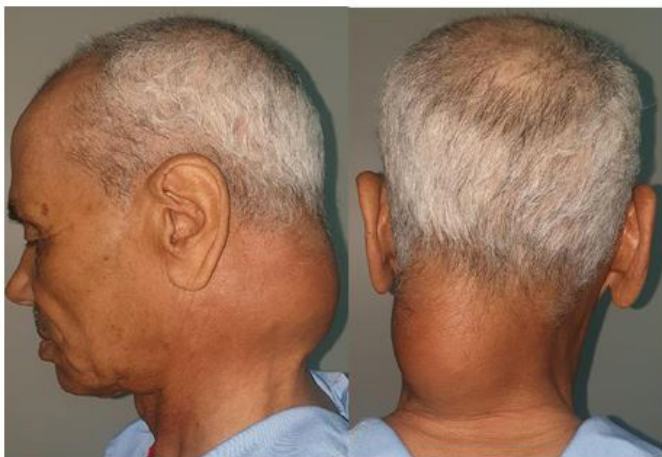

Figure 1: occipital mass overflowing on the nuchal region

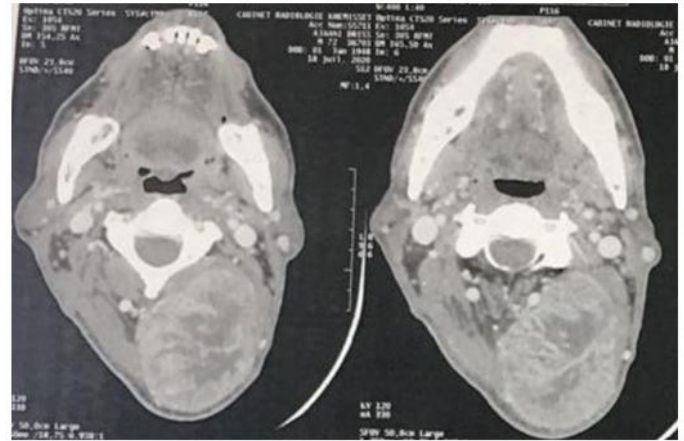


Figure 2: CT scan showing a heterogeneous occipital tissue containing areas of central necrosis

Under general anesthesia, we started with intra-operative frozen section that showed pleomorphic cells with enlarged hyperchromatic nuclei and eosinophilic cytoplasm. The surgery was completed by a large excision of the tumor limited by the cervical spine.

A histopathological examination of the surgical specimen showed pleomorphic cells with enlarged hyperchromatic nuclei and eosinophilic cytoplasm.

Immunohistochemical testing detected neoplastic cells expressing desmin, myogenin, CK AE1/AE 3, EMA, AML, H-caldesmon, CD 34, CD 31, KI67, and not expressing the HMB45, Melan A and the PS100; confirming the diagnosis of pleomorphic rhabdomyosarcoma.

Computerized tomography (CT) examinations of the abdomen and thorax revealed no metastases, and no lymphadenopathy was detected in the neck.

The follow-ups were simple, the patient underwent adjuvantive chemotherapy to eradicate any residual tumors.

## Discussion

Rhabdomyosarcoma is a common tumor in children with all its types. About 30% of pediatric rhabdomyosarcoma occurs in the head and neck [1]. Which is the opposite for adults where the head and neck sarcoma represented only 1% of all head and neck cancers [4].

The common type in adults is the pleomorphic rhabdomyosarcoma but it is very rare in the head and neck region. In addition, this tumor has a higher rate of recurrence and metastasis in adults [3].

The clinical presentation of the head and neck rhabdomyosarcoma depends on its location, the patients usually present a rapidly growing, painless, swelling [4,5]. The radiological examination that can be used to identify the extension of the tumor in this region are the cranio-facial CT scan or an MRI.

The diagnosis of the pleomorphic RMS is made by the histopathologic study, that usually shows a large, atypical pleomorphic tumor cells with abundant eosinophilic cytoplasm which can be irregular and hyperchromic, they also can have large or multiple nuclei. The diagnosis is confirmed by the immunohistochemical tests, the tumor cells express desmin, actin, myogenin, Myoglobin, Vimentin and MyoD1 [3-5].

Differential diagnosis of a head and neck mass should always be considered to avoid any misdiagnosis and mistreatment of the patients. Other malignant tumors with rhabdomyosarcomatous differentiation need to be considered on the differential diagnosis. Such as neuroblastoma, lymphoma, melanoma, fibrosarcoma, granular cell myoblastoma, rhabdomyoma, Ewing's sarcoma, chordocarcinoma and sarcomatoid carcinoma etc [4].

For our patient, the immunohistochemistry test confirmed the diagnosis by the presence of desmin, actin and myogenin, which are highly sensitive and specific markers for RMSs

RMSs are locally aggressive and they can spread regionally, or distantly by both lymphatic and hematological routes. The commonest sites of metastatic spread are lung, liver, lymph node and bone [6]. Therefore, during follow up, Computerized tomography (CT) examinations of the abdomen and thorax are essential to search any metastases or lymphadenopathy in the neck.

Several prognostic indicator are used to evaluate the prognosis of the RMS, which include, age, tumor location, size, histologic subtype, and the presence or absence of regional nodes or distant metastases. The age seems to be the most important prognosis factor, studies showed that Children treated for RMS had a significantly better outcome than adults regardless the subtype of the RMS [6].

The treatment of patients with malignant mesenchymal tumors of the head and neck region is multidisciplinary and multimodal includes radical surgery with postoperative radiotherapy and or chemotherapy.

The surgical excision of the tumor should be radical to prevent any local recurrence. The analysis of the specimen and the assessment of the extent of the tumor allow to establish the stage of the tumor according to the Intergroup Rhabdomyosarcoma Study (IRS) [7].

Radiotherapy is also an integral part of the treatment. The irradiation targets the tumor and the lymph nodes. It is not systematic, it is used as adjuvant therapy for small volume residual disease after surgery [8].

chemotherapy contributes to improved survival and reduced frequency of recurrence, also reduces the indications of extensive surgical excisions.

However, in high-risk metastatic forms, the treatment approach can be more conservative, partial surgical excision or non-surgical therapies such as radiotherapy and or chemotherapy [8].

In our case, the clinical and radiological presentation of the tumor didn't give us a diagnosis orientation. That is why we proceeded by an intra-operative frozen section that showed the presence of signs of malignancy. So we proceeded by the resection of the tumor with wide margins

The histological test of the surgical specimen confirmed the diagnosis of pleomorphic rhabdomyosarcoma and the total excision of the tumor. However, considering the malignancy and the metastatic potential of the tumor and the age of the patient, he was referred to the oncology center for a complement of radiotherapy.

## References

1. Sultan I, Qaddoumi I, Yaser S, Rodriguez-Galindo C, Ferrari A (2009) Comparing adult and pediatric rhabdomyosarcoma in the surveillance, epidemiology and end results program, 1973 to 2005: an analysis of 2,600 patients. *J Clin Oncol* 27: 3391–7.
2. Fletcher CDM, Unni KK, Mertens F (2006) WHO classification of tumours: pathology and genetics of tumours of soft tissue and bone. 3rd ed. Skeletal muscle tumors. 2006, Lyon: IARC Press, 141-54.
3. Eleanor Chen, Robert Ricciotti, Neal Futran, Dolphine Oda (2017) Head and Neck Rhabdomyosarcoma: Clinical and Pathologic Characterization of Seven Cases. *Head and Neck Pathol* 11: 321-6.
4. Zhou DN, Yang QQ, Li ZL, Pan ZY, Deng YF (2015) Head and neck rhabdomyosarcoma: follow-up results of four cases and review of the literature. *Int J Clin Exp Pathol* 8: 4277–83.
5. Furlong MA, Mentzel T, Fanburg-Smith JC (2001) Pleomorphic rhabdomyosarcoma in adults: a clinicopathologic study of 38 cases with emphasis on morphologic variants and recent skeletal muscle-specific markers. *Mod Pathol* 14: 595–603.
6. B Pittore, G Fancello, P Cossu Rocca, GP Ledda, G Tore (2010) “Rhabdomyosarcoma: a rare laryngeale neoplastic entity: a case report,” *Acta Otorhinolaryngologica Italica* 30: 52–57.
7. Parham DM, Barr FG (2013) Classification of rhabdomyosarcoma and its molecular basis. *Adv Anat Pathol* 20: 387–97.
8. Sevdegül Mungan, Selçuk Arslan, Eda Küçükütülü, Fafak Ersöz, Bengü ÇobanoLlu (2016) Pleomorphic Rhabdomyosarcoma Arising from True Vocal Fold of Larynx: Report of a Rare Case and Literature Review. *Case Rep Otolaryngol* 2016: 8135967.

**Submit your manuscript to a JScholar journal and benefit from:**

- ☞ Convenient online submission
- ☞ Rigorous peer review
- ☞ Immediate publication on acceptance
- ☞ Open access: articles freely available online
- ☞ High visibility within the field
- ☞ Better discount for your subsequent articles

Submit your manuscript at  
<http://www.jscholaronline.org/submit-manuscript.php>