

## A Pulmonary Metastasis of a Mixed Germ Cell Tumor of Testis with Active Covid-19 Infiltration of the Lungs

Aydin Hasan\*, Bilgin Yaltirik Ezel, Özdemir Yasin

Department of Radiology, Ankara Onkoloji Education and Research Hospital, University of Health Sciences, Turkey

\*Corresponding author: Aydin Hasan, Department of Radiology, Ankara Onkoloji Education and Research Hospital, University of Health Sciences, Turkey, Tel: 0090-312 3360909, 00905326413584, Email: dr.hasanaydin@hotmail.com

Received Date: May 03, 2022 Accepted Date: May 20, 2022 Published Date: May 22, 2022

Citation: Aydin Hasan, Bilgin Yaltirik Ezel, Özdemir Yasin (2022) A Pulmonary Metastasis of a Mixed Germ Cell Tumor of Testis with Active Covid-19 Infiltration of the Lungs. J Cancer Res Therap Oncol 10: 1-6

### Abstract

Testicular tumors comprise 1% of male neoplasms and 5% of urological tumors, with 3–10 new cases occurring per 100,000 males/per year in Western countries. Nonseminomatous germ cell tumors of the testis are common and are very aggressive malignant tumors, most of the cases have metastases at the time of diagnosis. Yolk sac tumor and teratoma are the most common components of the mixed type.

Here, we report a case with images about the pulmonary metastasis of a mixed germ cell tumor of testis with active Covid-19 infiltration of both lungs.

**Keywords:** Pulmonary, Metastasis, Covid, Infiltration, Testis

## Introduction

Testicular tumors comprise 1% of male neoplasms and 5% of urological tumors, with 3–10 new cases occurring per 100,000 males/per year in Western countries [1]

Nonseminomatous germ cell tumors of the testis are common and are very aggressive malignant tumors, most of the cases have metastases at the time of diagnosis, and involvement of hemithoraxes is particularly well known [1,2]

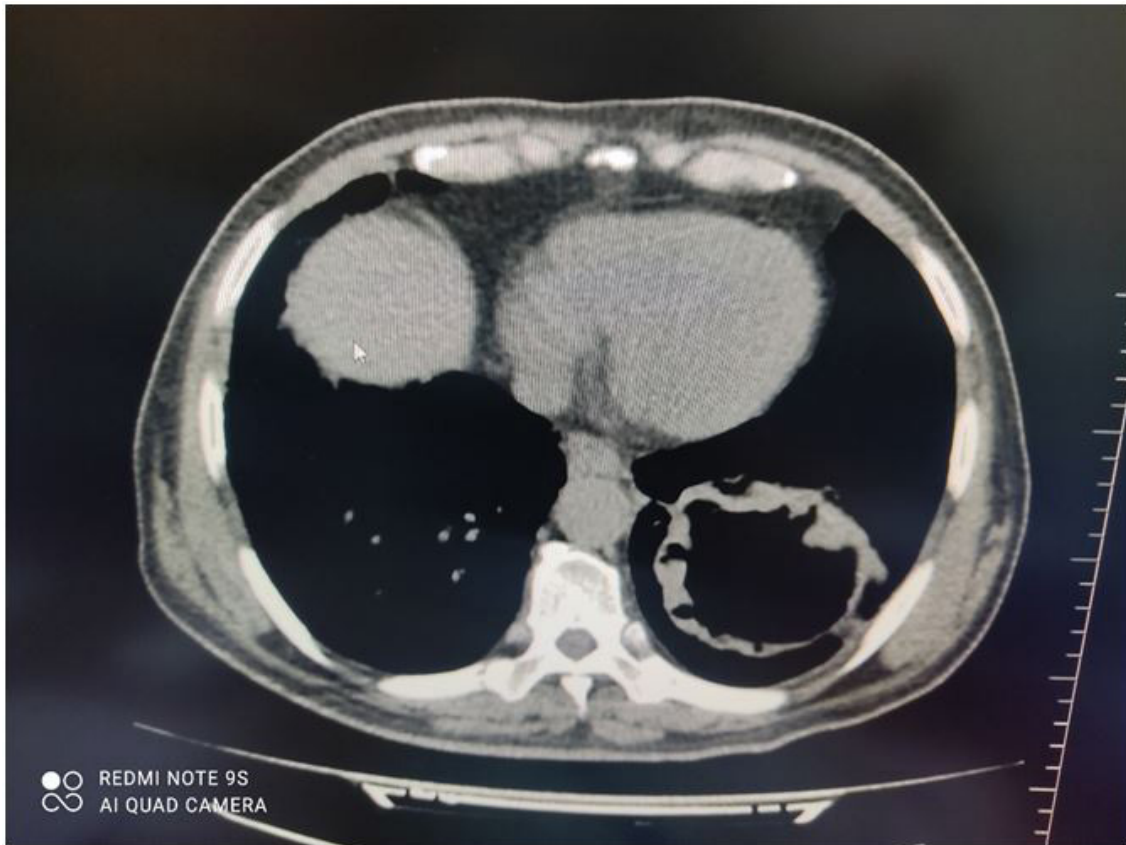
Most of the nonseminomatous germ cell tumors contain two or more germ cell components and are thus classified as mixed germ cell tumors [2,3] Although pure germ cell tumors are extremely rare in adulthood, mixed tumors comprise about 33% of all germ cell tumors [1,2].

## Case Report

Our patient was 61 years old with left orchiectomy history, had left testicular mixed germ cell tumor anamnesis about 3 years ago(%40 seminoma %60 choriocarcinoma).

He had cough,fever,hemoptysis with weight loss as a chief complaint, In the laboratory tests, alpha-feto protein was 15.62(0-8.8ug/L),beta-HCG level was 271.27(0-5ug/L),LDH was 426(0-247ug/L),he was referred to our department for Thorax CT.

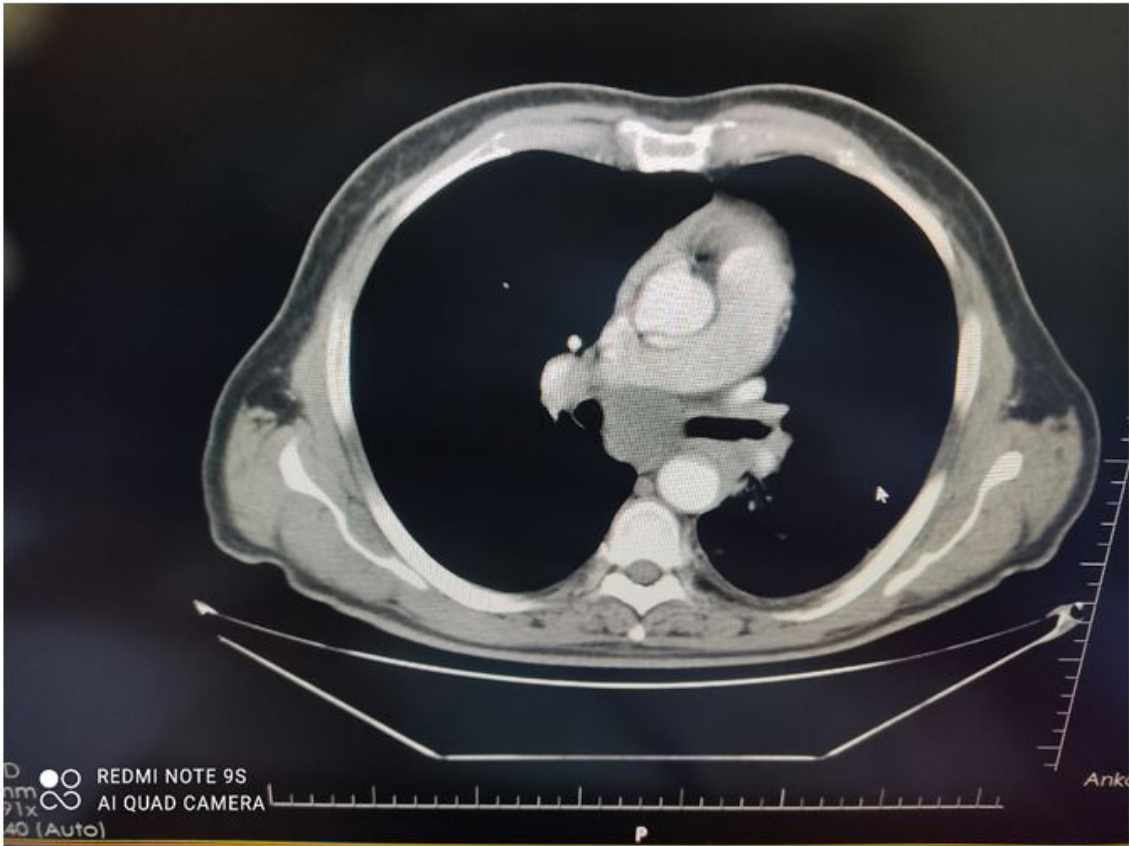
In the Thorax CT; Mediastinal,bilateral hilar and subcarinal pathologic lymph nodes were observed with a highest dimension up to 45x30 mm (Figure1).



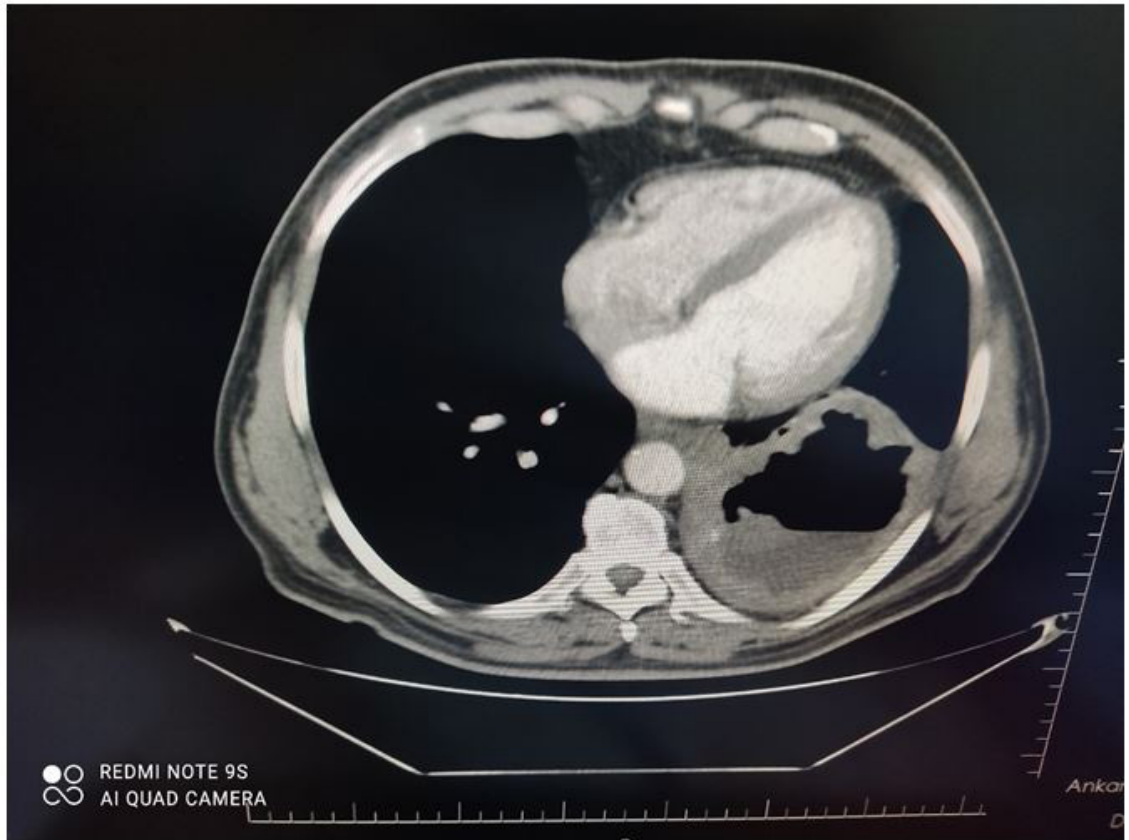
**Figure 1:** A hypodense subcarinal lymph node was observed in axial Thorax CT image

In the basis of left lung, a mass lesion about 10x9 cm in size with a large central cavitation was discovered, it had a disrupt thick heterogeneous wall with ill-borders(Figure 2-3)

This mass also had a tendency to spread to the left hilus and surrounded the bronchi of lower lobe, pulmonary artery and vein.

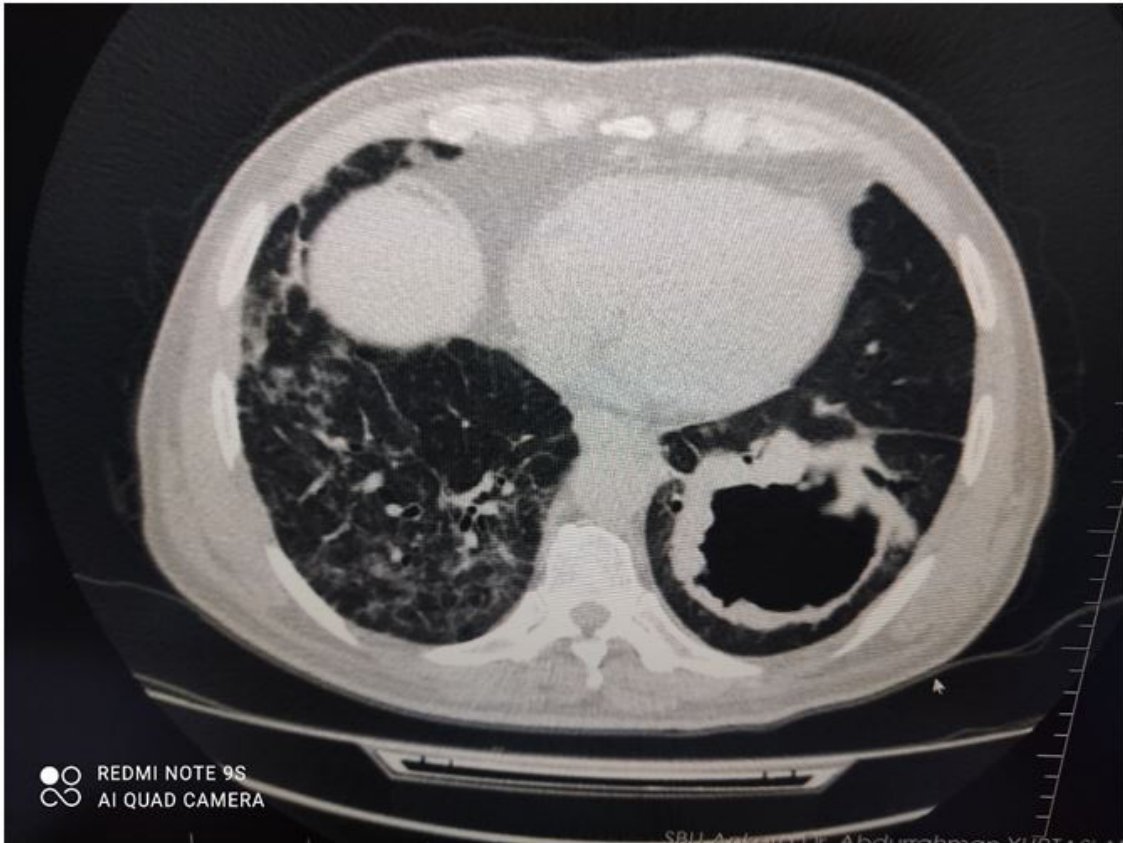


**Figure 2:** A left lung mass with a large central cavity, located in the posterobasal segment, cavity had an ill-defined thick border

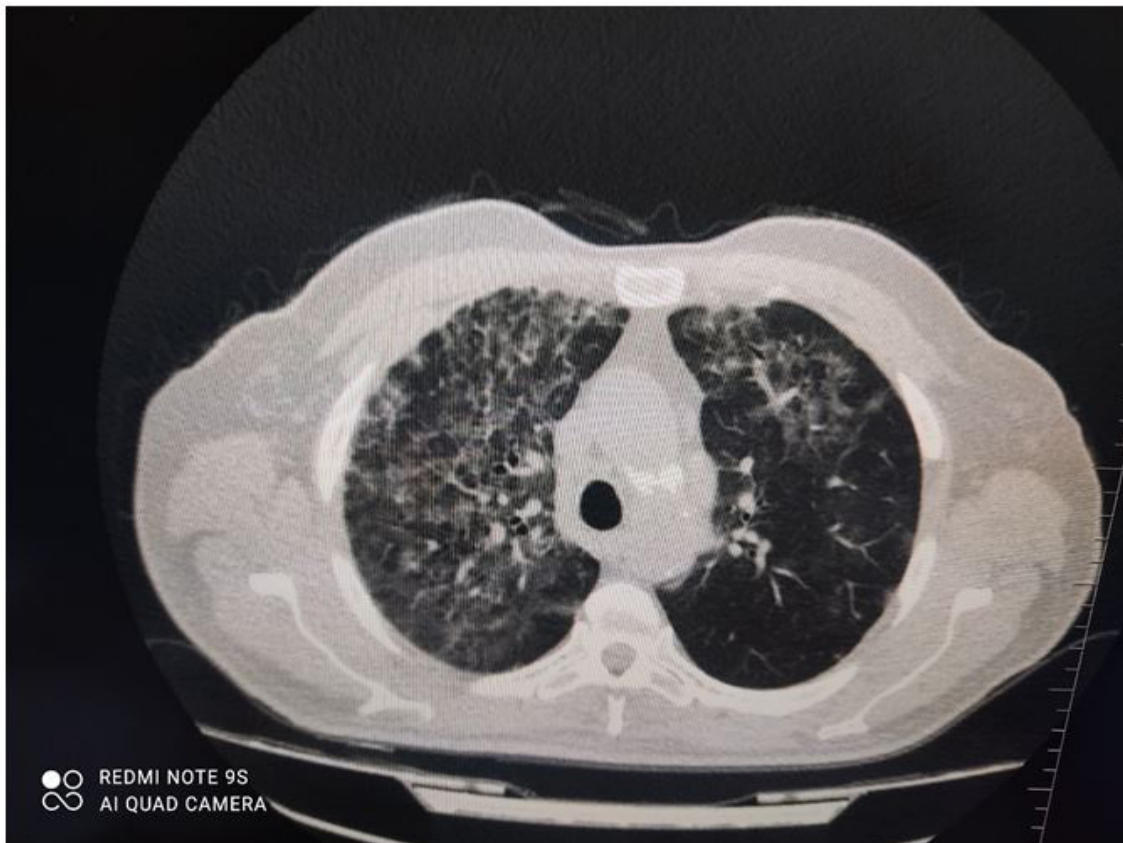


**Figure 3:** This mass also showed necrosis and cavity-cystic contrast with thick irregular wall

Bilateral multifocal infiltrations in terms of ground-glass appearance were visualized in both hemothoraxes with nodular pneumonic consolidated infiltrates especially in the peripheral parts of both lower lobes (Figure 4-5).



**Figure 4:** A large cavitated lung mass was seen in the left basis, ground-glass infiltration pattern was observed in the right lower lobe



**Figure 5:** Bilateral Covid-19 infiltration in both lungs, ground-glass pattern with multiple nodular consolidated infiltrates and subpleural opacities

True-cut biopsy for the lung mass yielded a result of pulmonary metastasis of mixed germ cell tumor, composition of this mixed germ cell tumor included both seminoma and choriocarcinoma. His PCR was also+ and antiviral Covid-19 therapy. had been admitted against the virus[Oral Favipiravir tab.+Oral prednisolone tab+Nasal O<sub>2</sub>+Conservative supplementary treatment(Hydration+VitC/D supplements etc.)].

Therapy was continued about 1 month till the complete resolution of SARS/CoV-2 infection. Chemoradiotherapy was decided to be applied as an appropriate treatment approach against pulmonary metastasis of mixed germ cell tumor .First of all, 2 cures Radiotherapy was being admitted between 05.02 to 05.04.2022 which was started about 1 month after the end of Covid-19 therapy. First cure chemotherapy was started at 05.05.2022 that had consisted of 4 cures, including Linoxa IV.inf 100 mg/20 ml.+ Gemko 1000 mg IV inf.+ Neoset 3 mg/3ml IV inf.+Dexoject IV inf.8mg/2 ml.

## Discussion

Pulmonary metastasis of mixed germ cell tumors is associated with secondary hemoptysis, retroperitoneal metastasis associated with back pain, gastrointestinal system metastasis with gastrointestinal bleeding, and brain metastasis with neurological symptoms [4,5].

In non-seminomatous tumors, advanced stages (IIC and III) are considered to be poor prognosis when associated with any of the following criteria: visceral metastases, AFP >10.000 ng/ml, HCG >50.000 IU/l or LDH >10 × ULN(1-5)

The differential diagnosis of Lung cavities is large and includes various infections, autoimmune conditions, primary and metastatic malignancies. An acute or subacute process (< 12 weeks) suggests common bacterial and uncommon nocardial and fungal causes of pulmonary abscesses, necrotizing pneumonias, and septic emboli. A chronic process (≥ 12 weeks) suggests mycobacterial, fungal, viral, or parasitic infections; malignancy(primary lung cancer especially squamous type or metastases) or autoimmune disorders(rheumatoid arthritis and granulomatosis with polyangiitis) (6). Covid-19 pneumonia, Tuberculosis, Pulmonary Aspergillosis, pulmonary echinococcosis were the most common associated infections, seen within the metastatic lung cavities(6-8).

In our patient, any infections within the cavitated mass were not observed. Potential sustainable infections within the cavitated metastasis, can be eliminated by Anti-covid therapy, by using anti-tuberculosis drugs, by antifungal treatment and by administration of anti-parasiter tablets.

## Conclusion

A heterogeneous disrupted left lung mass with an active Covid-19 infiltration in both hemithoraxes were observed and histopathological diagnosis revealed a pulmonary metastasis of a mixed germ cell tumor. He had taken antiviral therapy and after resolution of outcome of the SARS-CoV-2 infection, he had been admitted into Radiotherapy at first and now was under chemotherapy cure as the treatment approach.

## References

1. Pushpanjali B, Arvind A and Minakshi Bhar (2021) Pure yolk sac tumor of testis with lung metastasis in an adult patient - case report. *Med Pharm Rep* 94: 252-255.
2. Murcia JDU, Ochoa MAS, Manrique IAV, Herrera JMS (2017) Pure Yolk Sac Testicular Tumor in an Adult Patient: Case Report. *Oncol Cancer Case Rep* 3: 139.
3. Wang Z, Yan B, Wei YB, Yin Z, Zhou KQ, Yang JR (2015) Adult metastatic yolk sac tumor descending from an intra-abdominal testis: A case report and review of the literature. *Oncol Lett* 10: 3647-3650.
4. Emre D, Serkan A, Zafer D, Mehmet K, Bengü D, et al. (2018) Radiological nodule behavior: A critical parameter in the surgical management of pediatric pulmonary metastases. *Turk J Pediatr* 60: 372-379.
5. Konstantinos S, Panagiotis P, Georgios P, Nikolaos G, Michalis O, et al. (2009) Mixed germ cell tumor of the testicle with raviduomuosarcomatous component: a case report. *Cases J* 2: 9299.
6. Khalid G, Shalin P, Francis G, Nishant G, David N, Stephen M, et al. (2018) Cavitory Lung Diseases: A Clinical-Radiologic Algorithmic Approach *Chest* 153: 1443-1465.
7. Mifsud S, Schembri EL, Gauci J, Mizzi A, Mallia Az-zopardi C, et al. (2017) The non-resolving lung cavity: a case of pulmonary cystic echinococcosis. *BMJ Case Rep* 2017: bcr2017220909.
8. Kurys-Denis E, Grzywa-Celińska A, Celiński R (2021) Lung cavitation as a consequence of coronavirus-19 pneumonia. *Eur Rev Med Pharmacol Sci* 25: 5936-5941.

### Submit your manuscript to a JScholar journal and benefit from:

- ✦ Convenient online submission
- ✦ Rigorous peer review
- ✦ Immediate publication on acceptance
- ✦ Open access: articles freely available online
- ✦ High visibility within the field
- ✦ Better discount for your subsequent articles

Submit your manuscript at  
<http://www.jscholaronline.org/submit-manuscript.php>