

Severe Tricuspid Insufficiency as a Manifestation of Neonatal Lupus

Merchan Erika Fernanda¹, Carretero Bellon J^{1,3,*}, Morr Igor C³, Sanchez De Toledo J¹, Congiu Stefano²

¹Pediatric Cardiology Department

²Pediatric Cardiac Surgery Department, Sant Joan de Deu Hospital, Esplugues Llobregat, Spain

³Pediatric Cardiology Unit Hospital Joan XXIII Tarragona. Universitat Rovira I Virgili, Tarragona, Spain

*Corresponding author: Juan M. Carretero MD, Sant Joan de Dèu Hospital, Paseo Sant Joan de Dèu, 2 Esplugues 08950, Barcelona – Spain, Tel: +34 932 53 21 00; E-mail: jcarretero@sjdhospitalbarcelona.org

Received Date: September 13, 2019 Accepted Date: October 24, 2019 Published Date: October 26, 2019

Citation: Merchan Erika Fernanda (2019) Severe Tricuspid Insufficiency as a Manifestation of Neonatal Lupus. J Cardio Vasc Med 5: 1-6.

Abstract

Valve dysfunction is an infrequent condition in infants of anti-Ro/SSA-positive pregnancies, but a few cases have suggested an association between rupture of the atrioventricular (AV) valve tensor apparatus and maternal anti-Ro/SSA antibodies. In the present study, we describe a patient with severe tricuspid insufficiency due to a flail, whose mother has an asymptomatic rheumatological disorder, and the progression from fetal life to the moment surgery was performed.

Keywords: Flail of the tricuspid valve; Lupus; Neonate

Introduction

Neonatal lupus (NL) describes a clinical spectrum of cardiac and non-cardiac abnormalities observed in neonates and fetuses whose mothers have the auto-antibodies anti-SSA/Ro (anti-Ro) and anti-SSB / La (anti-La). Congenital complete heart block is the most common and (recognized) well-known cardiovascular manifestation of NL that can occur in utero or after birth. Nonetheless, manifestations such as endocardial fibroelastosis (EFE), pericarditis, myocarditis, cardiomyopathy or coronary artery disease may occur [1].

Valve dysfunction is an infrequent condition in infants of anti-Ro/SSA-positive pregnancies, but a few cases have suggested an association between rupture of the atrioventricular (AV) valve tensor apparatus and maternal anti-Ro/SSA antibodies. Different hypotheses for the mechanism by which these antibodies mediated the condition been suggested [1,2].

In the present study, we describe the case of a patient with valve dysfunction secondary to rupture of the papillary muscle of the tricuspid valve affected by maternal anti-Ro antibodies and we review the published data for infants of anti-Ro positive pregnancies with A-V valve insufficiency due to chordal rupture of the papillary muscles.

Case report

A 26-year-old first-gravida mother was checked routinely at 20 weeks of gestation. Fetal echocardiogram showed a structurally normal heart and focal areas of increased echogenicity at the level of the papillary muscles and chordae of both atrioventricular (AV) valves (Figure 1). The heart rhythm was normal. Rheumatologic prenatal profile was positive for anti-Ro and anti-La antibodies and the mother was completely asymptomatic during pregnancy.

During the following weeks, those patchy echogenicity areas almost disappeared and only minimal residual patchy infiltrates limited to the tricuspid valve chordae were seen on an otherwise normal echocardiogram. Neither insufficiency nor stenosis was detected. Routine follow-up at 39 weeks of gestation showed pleural effusion that required ultrasound-guided drainage. Emergency cesarean section was performed due to fetal hydrops. A 2.2 kg female newborn was delivered and soon after birth required high-frequency ventilation and nitric oxide therapy in association with diuretic and inotropic support.

Postnatal echocardiogram showed normal biventricular function and severe tricuspid regurgitation, showing prolapsed leaflets that fail to line up correctly. An echo-image of

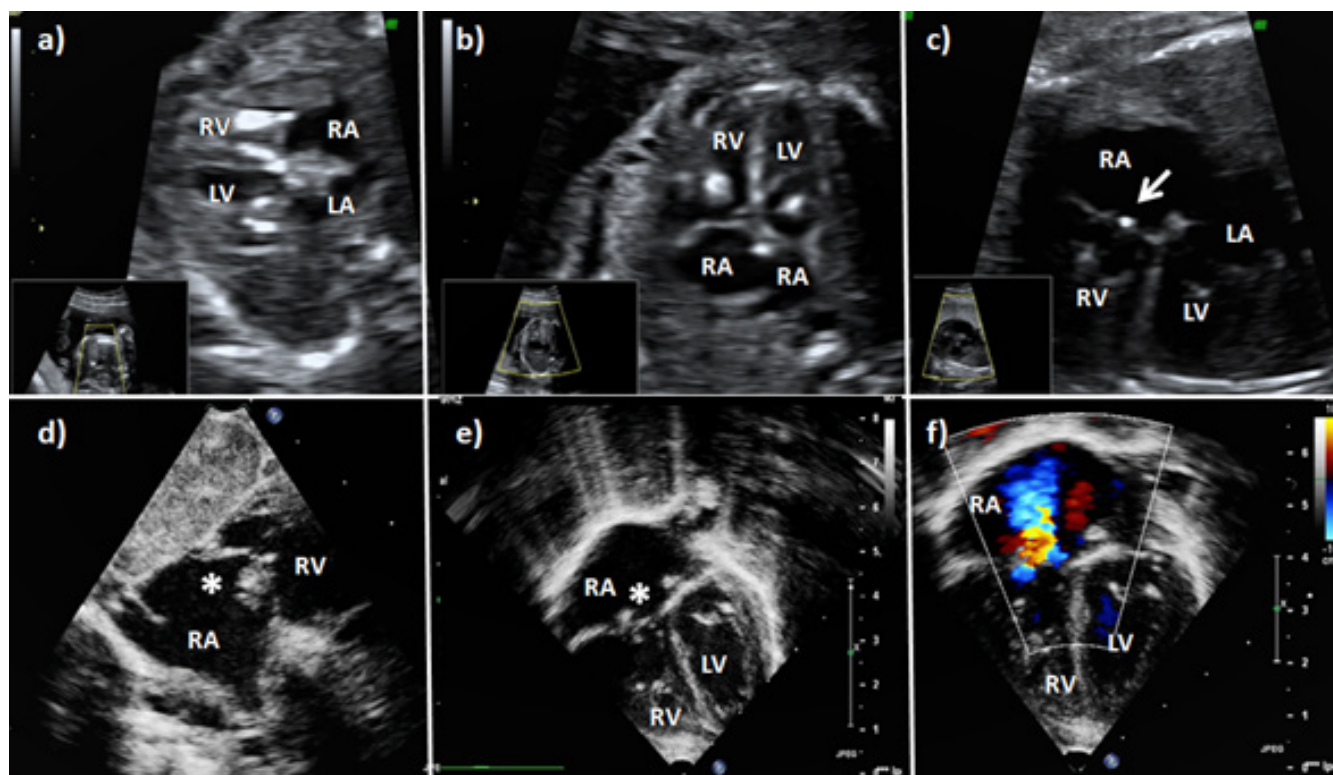


Figure 1: A two-dimensional fetal echocardiogram (a-c) with localized areas of increased echogenicity at the papillary muscles of both AV valves. The last fetal echocardiogram (c) showed minimal residual echo bright density limited to the tricuspid valve (arrow). Postnatal echocardiogram showed the tricuspid valve with an image resembling vegetation (asterisk) and, by color-flow Doppler, severe insufficiency of the tricuspid valve (d-e). RV: right ventricle. RA: right atrium. LV: left ventricle. LA: left atrium.

vegetation-like outgrowths on both the anterior and lateral veils measuring 4-5 mm in diameter that looked like vegetation (Figure 1) was seen that probably correspond to a flail of the anterior tricuspid valve leaflet. Moreover, an interatrial communication with bidirectional shunt along with pulmonary hypertension was detected. We observed no areas of hyper refringency either at the interventricular septum or at the papillary muscles.

The laboratory study was positive for anti-Ro antibodies and negative for anti-La. ANA and anticardiolipin were negative as well. A heterozygous mutation of factor V Leiden was detected.

Tricuspid valve insufficiency worsened and transesophageal echocardiography revealed that the mechanism of the regurgitation was due to a flail of the anterior tricuspid valve leaflet.

The patient was operated through a median sternotomy. Cardiopulmonary by-pass was achieved and after aortic cross-clamp, the heart was stopped with the infusion of antegrade hematic cold cardioplegia. A longitudinal auriculotomy showed a free prolapse of the anterior leaflet due to missing papillary muscle and respective chordae attachments. The free wall of the right ventricle was hypertrophic and a thick bundle muscle was partially detached from the free wall of the right ventricle to be used as a neo-papillary muscle. Then the anterior leaflet of the tricuspid valve was directly attached to the neo-papillary muscle with 5/0 prolene used as neo chordae. A tricuspid annuloplasty was performed with 5/0 prolene (Figure 2) from the posterior leaflet anticlockwise to the commissure between the anterior and septal leaflets to stabilize the repair. The atrial septal defect was closed with a direct suture of polypropylene 6/0. Biopsy specimens obtained from the right ventricle revealed inflammatory changes and fibrosis.

A routine echocardiographic control at the age of 8 years demonstrated normal biventricular function and mild tricuspid insufficiency. She is currently asymptomatic without medication.

Discussion

NL is a passively-acquired autoimmune disease due to the transplacental transfer of maternal antibodies to the fetus. An estimated 2–3 % of pregnant women carry the anti-Ro antibodies. The most common acquired disorders are systemic lupus erythematosus (LES) and Sjogren's syndrome. NL can be present in asymptomatic mothers with positive antibodies [2].

The fetal injury occurs as a consequence of the transplacental passage of maternal autoantibodies against the intracellular ribonucleoproteins 48-kDa SSB/La, 52-kDa SSA/Ro, and 60-kDa SSA/Ro. SSA / Ro is a complex system that comprises at least two 52 and 60 kD molecular weight polypeptides, respectively. A small central portion of 52 kD Ro, from 200 to 239 amino acids, called p200 seems to have a major role since it could represent the specific region of the union of the anti-Ro associated with congenital heart block [1].

The cardiac manifestations associated with NL are the most serious. Although the most common disorder reported in the literature is complete heart block, which accounts for up to 60-90% of all congenital heart blocks [2], several manifestations have been reported, some of them not well known.

The clinical and serological features of NL syndrome have been extensively described; however, publications detailing the anatomical pathology findings in the heart are limited [3,4]. The majority of the initially reported cases have shown fibrosis and/or calcification of the atrioventricular (AV) node, but the disease can also extend to other areas of the conduction system, including the findings of progressive sinus node and infrahisian conduction system abnormalities, atrial flutter and, in several cases, sinoatrial (SA) nodal scarring has been described [5,6,7,8]. EFE has been previously demonstrated in pathology studies of anti-Ro/La-exposed fetuses with and without the presence of heart block, and it is currently acknowledged as part of the spectrum of cardiac NL [3,9,10,11].

Valvular abnormalities have been only rarely reported. Nield et al [10]. described dystrophic and calcified mitral valve papillary muscles in the post-mortem study of an anti-La positive but anti-Ro negative female fetus with diffuse EFE, as well as calcification of the SA and AV nodes. Litsey et al [12] have previously reported one of the cases with tricuspid valve dysplasia. Although the papillary muscles and chordae of the AV valves are common sites of patchy echogenicity, severe AV-valvular insufficiency due to dysfunction of the tensor apparatus has rarely been reported [1].

Cuneo et al. [4] has described several cases of fetal endocardial fibroelastosis with rupture of the valvular tensor apparatus. One of the afore-mentioned is an anti-Ro / SSA-positive case, in which the patient presented fetal endocardial fibroelastosis and postnatal echocardiogram with increased echogenicity at the level of the tricuspid valvular apparatus. Spontaneous interruption of the tensioning device of the AV valve could also be seen, as well as severe tricuspid insufficiency. Consequently, the patient required surgery in which interruption of the anterior valvular junctions from the head of the papillary muscle was

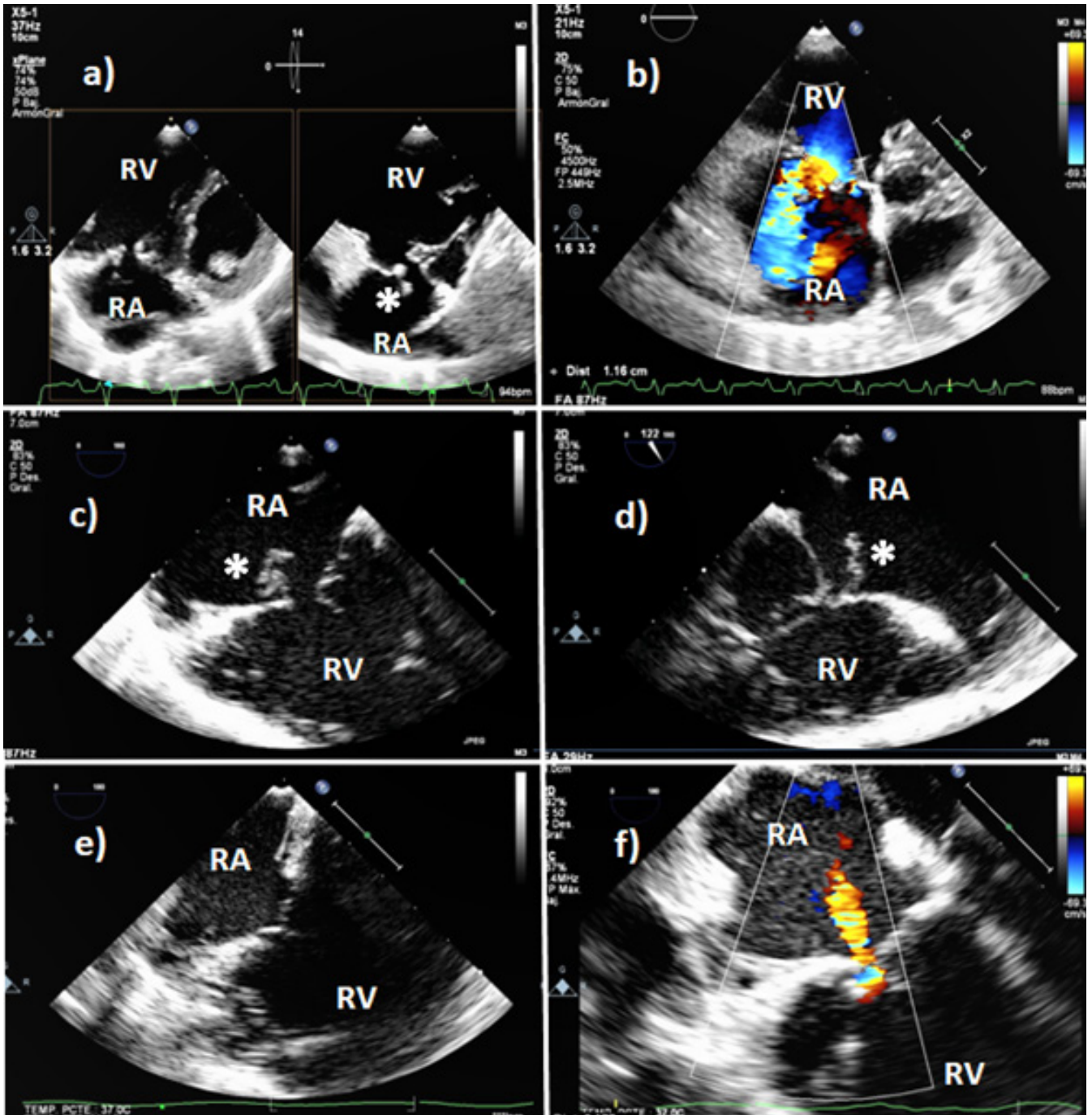


Figure 2: Transthoracic (a-b) and transesophageal echocardiogram (c-d) showed a flail of the anterior leaflet of the tricuspid valve (asterisk) with severe regurgitation and dilatation of the right ventricular cavities. Transesophageal postoperative images showing the normal alignment of the tricuspid valve and mild regurgitation (e-f). RV: right ventricle. RA: right atrium. LV: left ventricle. LA: left atrium.

found. The surgeons replaced the broken ropes with Gore-Tex 5-0. The evolution presented by the patient after a repair was favorable [4].

Gonzalez et al. [13] have also described a case of a patient with an anti-SSA / Ro and anti-SSB-La positive mother, who showed signs of myocarditis in the fetus during controls, with lesions at the level of the tricuspid anterior papillary muscle with tricuspid insufficiency. Two months after birth, the newborn required repair of the tricuspid valve with fixation of the papillary muscle without annuloplasty, presenting a good evolution after surgery [13].

The last of the afore-mentioned cases related to tricuspid valve dysplasia has been reported by Fleming et al. [14] in which a mother presented prenatal diagnosis with anti-SSA / Ro positive. The fetus had complete AV block and fibroelastosis. The presence of an alteration in the papillary muscles and pulmonary stenosis was confirmed after birth, which required a pacemaker placement. 3 months afterward, there was an emergency in which the newborn presented a 50% saturation. The echocardiogram showed a bright echo in the distal papillary muscle with severe tricuspid regurgitation. The newborn was taken to surgery, where the rupture of the distal portion of the anterior papillary muscle was confirmed and repaired. The evolution is seen in the patient after surgery was favorable [14].

The pathogenesis of the papillary muscle chordal rupture may be similar to that proposed for the autoimmune AV block. Maternal anti Ro/La antibodies bind to fetal cardiocytes and inhibit the normal physiological removal of these apoptotic cells, resulting in inflammatory reaction and fibrosis of the cardiac conduction system. In the same way that autoantibodies bind to the specialized cells of the conduction system, they would also bind to the cardiac myocytes at the cords and/or the papillary muscles, evoking an inflammatory response with subsequent fibrosis and, ultimately, muscle chordal rupture [1].

Despite the scarcity of cases reported, there is some evidence that the most important histopathological findings have shown severe atrophy with the replacement of the myocytes by fibrosis and dystrophic calcifications of the papillary muscles. This contrasts with the finding of no histopathological lesions on the VA leaflets, as has been reported in patients with anti Ro-mediated AV block. The reason may lie in the different embryological origin of the valves and cords, which derive from the endocardium, in contrast with the papillary muscles, which derive from the myocardium. As other studies suggest, the immune-mediated injury is directed directly at the myocardial-derived cell lines [4].

Perhaps the initial inflammatory insult could be suppressed, although to date preventive treatments such as maternal

steroids, intravenous immunoglobulin and plasmapheresis have not decreased the incidence, and their use in the prevention of heart block is currently very controversial. Maybe maternal exposure to hydroxychloroquine may decrease the risk of cardiac NL [15].

The spectrum of maternal anti-Ro/anti-La antibody-associated with fetal cardiac disease may have previously been underappreciated. Valvular abnormalities in the setting of anti-Ro-positive pregnancies have rarely been reported. We have described the rare clinical picture of a patient whose mother had anti-Ro-positive antibodies, resulting in AV valve insufficiency due to chordal rupture from the papillary muscles. These findings, taken together with the other valvular abnormalities reported in the bibliography, support the evaluation of anti-Ro/La antibodies in the mothers of children with more diffuse but unexplained valvular defects.

References

1. Morel N, Georgin-Lavialle S, Levesque K, et al. (2015) «Lupus néonatal»: Revue de la littérature. *Rev Med Interne* 36: 159–166.
2. Miner JJ, Kim AHJ (2014) Cardiac Manifestations of Systemic Lupus Erythematosus. *Rheum Dis Clin North Am* 40: 51–60.
3. Nield LE, Silverman ED, Taylor GP, et al. (2002) Maternal anti-Ro and anti-La antibody - Associated endocardial fibroelastosis. *Circulation* 105: 843–848.
4. Cuneo BF, Fruitman D, Benson DW, et al. (2011) Spontaneous rupture of atrioventricular valve tensor apparatus as a late manifestation of anti-Ro/SSA antibody-mediated cardiac disease. *Am J Cardiol* 107: 761–766.
5. Cuneo BF, Strasburger JF, Niksch A, et al. (2009) An expanded phenotype of maternal SSASSB antibody-associated fetal cardiac disease. *J Matern Neonatal Med* 22: 233–238.
6. Apur RAJPK (1998) Congenital Heart Block and Associated Cardiac Pathology in Neonatal Lupus Syndrome AND 136–142.
7. Bharati S, Swerdlow MA, Vitullo D, et al (1987) Neonatal Lupus with Congenital Atrioventricular Block and Myocarditis. *Pacing Clin Electrophysiol* 10: 1058–1070.
8. Chameides L, Truex RC, Vetter V, et al. (1977) Association of Maternal Systemic Lupus Erythematosus with Congenital Complete Heart Block. *N Engl J Med* 297: 1204–1207.
9. Izmirly PM, Kim MY, Llanos C, et al. (2010) Evaluation of the risk of anti-SSA/Ro-SSB/La antibody-associated cardiac manifestations of neonatal lupus in fetuses of mothers with systemic lupus erythematosus exposed to hydroxychloroquine. *Ann Rheum Dis* 69: 1827–1830.
10. Nield LE, Silverman ED, Smallhorn JF, et al. (2002) Endocardial fibroelastosis associated with maternal anti-Ro and anti-La antibodies in the absence of atrioventricular block. *J Am Coll Cardiol* 40: 796–802.
11. Guettrot-Imbert G, Cohen L, Fermont L, et al. (2011) A new presentation of neonatal lupus: 5 Cases of isolated mild endocardial fibroelastosis associated with maternal anti-SSA/Ro and anti-SSB/La antibodies. *J Rheumatol* 38: 378–386.
12. Litsey SE, Noonan JA, O'Connor WN, et al. (1985) Maternal connective tissue disease and congenital heart block. Demonstration of immunoglobulin in cardiac tissue. *N Engl J Med* 10: 98–100.
13. González-López MT, Pérez-Caballero-Martínez R, Gil-Jaurena JM (2017) Myocarditis, flail tricuspid valve, and normal rhythm: An exceptional form of neonatal cardiac lupus. *Cardiol Young* 27: 1419–1422.
14. Fleming GA, Scholl FG, Kavanaugh-McHugh A, et al. (2008) A case of an infant with flail tricuspid valve due to spontaneous papillary muscle rupture: Was neonatal lupus the culprit? *Pediatr Cardiol* 29: 442–445.
15. Gleicher N, Elkayam U (2013) Preventing congenital neonatal heart block in offspring of mothers with anti-SSA/Ro and SSB/La antibodies: A review of published literature and registered clinical trials. *Autoimmun Rev* 12: 1039–1045.

Submit your manuscript to a JScholar journal and benefit from:

- ¶ Convenient online submission
- ¶ Rigorous peer review
- ¶ Immediate publication on acceptance
- ¶ Open access: articles freely available online
- ¶ High visibility within the field
- ¶ Better discount for your subsequent articles

Submit your manuscript at
<http://www.jscholaronline.org/submit-manuscript.php>