

## Designing of a Tool to Aid in Oral Dermatologic Diagnosis

M. Le Coat<sup>1,\*</sup>, M. Lenoel<sup>1</sup>, G. Bader<sup>2</sup>

<sup>1</sup>Odontology Service, University of Rennes 1, Rennes University Hospital, France

<sup>2</sup>Oral Surgery Service, University of Rennes 1, Rennes University Hospital, France

\*Corresponding author: Marine Lenoel, Odontology service, University of Rennes 1, Rennes University Hospital, France, Tel: 0665123192; E-mail: marine-lenoel@hotmail.fr

Received Date: September 21, 2019 Accepted Date: October 26, 2019 Published Date: October 28, 2019

Citation: M. Le coat (2019) Creation of an Outil D'aide or Diagnosis in Oral Dermatology: Designing of a tool to aid in oral dermatologic diagnosis. J Dent Oral Health 6: 1-7.

### Summary

#### Introduction

Oral dermatology is a wide field and is often dentists' weakness. A tool was designed in order to aid in oral dermatologic diagnosis: <http://outildiagnosticdermatobuccale.fr/>. It is based on multiple criteria regarding the lesion observed by the physician.

#### Materials and Methods

A list of oral pathologies has been established, and some clinical features have been chosen to characterize them. Each type of lesion listed was assigned specific features, which were summed up in clinical sheets. Clinical sheets contain a definition, clinical signs, localization, differential diagnosis, and treatment plan. The most rare pathologies were disregarded in order to simplify the research. Illustrations have been linked to the pathologies to confirm the result or exclude others. The website was designed on Word Press, using Awesome Table for the drop-down menus. A guide for elementary lesions, a diagnostic approach, and bibliography were included. A Contact section was created to receive users' opinions. The website address was sent to Rennes University's teachers and students for a first try and then was spread more widely through social networks.

**Keywords :** dentistry; stomatognathic diseases; search engine; physical examination

#### Discussion

This tool does not replace a specialist consultation, but it can guide the clinician in the diagnosis and the elaboration of a treatment plan. The confrontation between the website result and a dermatology atlas is recommended.

## Introduction

Dentists are healthcare practitioners in the best position to detect and manage oral lesions. However, in front of a dermatological lesion, only a few of them are able to propose a diagnosis, reassure the patient and handle simple cases. Oral dermatology is a wide discipline and rare are the dentists who master it. A recent study showed that only 10% of French dentists try to diagnose and treat dermatological lesions themselves. It concludes that delays in the diagnosis of oral mucosal diseases are associated with a lack of experience and interest of French dentists in identifying these lesions [1]. Knowing this, a tool was designed to aid in oral dermatologic diagnosis. Another similar tool already exists, but only for one type of lesion (*Aide au diagnostic des lésions nodulaires de la muqueuse orale basée sur des critères cliniques: cas cliniques et création d'un site internet*, de H. Delebarre et Dr. H. Raybaud [2]). We wanted to create a complete tool including all types of oral lesions. Atlases [3, 4, 5, 6] offer very complete information but to use them efficiently the practitioner needs to have a previous diagnostic hypothesis. The purpose of this work was to create an alternative that would not demand specific knowledge except elementary lesions and basic dermatological lexicon used for clinical description. This tool is made to help the physician making a diagnosis when he encounters an oral dermatological lesion. Based on several discriminating criteria, the tool contains almost all of the oral lesions. On the website, criteria corresponding to the lesion are selected by the practitioner. One or several potential diagnoses appear. Each diagnosis is linked to a clinical sheet where there are clinical information, differential diagnosis, additional tests and a proposal for care. To be noted that a patient's history cannot be taken into account. The tool results are propositions to include in a general context. The form of the website was chosen for its interactivity and the possibility to make changes instantly. Indeed, the tool needs to be dynamic and follow scientific progress.

## Material and Methods

### Creation of the site's content

First of all, a list of oral dermatological lesions was made using existing documentation.

The list began with ulcerative lesions. Then it was extended to all types of lesions. This list includes both frequent and rare lesions. We wanted the inventory of lesions to be as complete as possible.

Secondly, diagnostic criteria were chosen to sort pathologies. The criteria chosen had to be accessible in a routine examination at the dental office. We followed the description of the lesions we found in dermatological atlases while reviewing literature. A dermatological lexicon was used to describe lesions.

Diagnostic criteria were chosen for their efficiency qualifying lesions and their simplicity of use. They are sorted by categories. For each category, a list of several criteria is available (Table 1). This list was modified many times: some categories were too difficult to use or didn't differentiate pathologies enough. These categories were not interesting for the search tool. The "form" category was too difficult to use: there were too many possible criteria, increasing the risk of a wrong diagnosis. Also, it was redundant with the "elementary lesion" category. The category "number of lesions" was a source of confusion in the case of multiple lesions growing into a large one.

To simplify the research, numerical values were gathered in intervals. For the size of a lesion, possibilities were reduced to four intervals (see Table 1). About the painful aspect of lesions, first thought was to use the VAPS (Visual Analog Pain Scale) but it was too patient-dependant. So we narrowed possibilities to painful or not painful. For a lesion that can be both, the tool is set in such a way that the practitioner can select "painful" or "not painful" and the lesion will be selected in both cases. The categories "general evolution" (containing "continuous" or "intermittent" criteria) and "date of the apparition" were rejected because they depend too much on previous observations made by the patient himself.

The definitive list contains nine categories, each with several associated possible criteria. Diagnostic criteria were then imputed to each lesion (Figure 1). Dermatological lesions can have many clinical aspects. That's why lesions have more than one criterion selected in one category, to include every known aspect. The objective was that a search could lead to the same diagnosis whatever the clinical variations of a lesion.

Type de lésion élémentaire	Taille	Couleur	Douloureux	Signes généraux	Texture à la palpation	limites/contour	Site/Localisation	Mode d'apparition
Atrophie	moins de 3 mm	rouge	oui	absents	dur	contour régulier	palais	brutal
Buîte	moins d'1 cm	blanc	non	adénopathies	fluctuant	limites irrégulières	langue	progressif
Croûte	1 à 3 cm	blanc jaunâtre		trismus/LOB	souple	non délimité	plancher de la langue	intermittent
Dépapillation	plus de 3 cm	gris		AEG	détachable	liseré érythémateux	gencive kératinisée	
Enanthème		noir		hypersalivation	lisse	bords surélevés	gencive libre et fond de vestibule	
Erosion		bleuté		halitose	ferme			
Erythème		violacé		dysphagie	surface irrégulière		oropharynx	
Exposition osseuse		brun		fièvre	induré		ganglions cervicaux	
Fissure		jaunâtre		atteinte digestive			lèvres	
Hypertrophie gingivale		orangé		atteinte laryngée			os maxillaire	
Hypertrophie linéaire		rose		atteinte ophtalmique			os mandibulaire	
Hypertrophie papillaire				atteinte respiratoire			intérieur des joues	
Hémorragie				céphalées				
Kératose				douleurs aux muscles de l'ATM				
Macule				dysgueusie				
Masse				fatigue				
Nodule				malaise				
Cedème				macrochéilite				
Papule				manifestations cutanées				
Plaque				manifestations naso-sinuasiennes				
Purpura				paralysie faciale				
Scièreose				paresthésie				
Tuméfaction				prurit				
Ulcération				rhinorrhée				
Vésicule				sensation de brûlure				
				toux				
				tuméfaction				
				xérostomie				

Table 1. List of criteria sorted by categories (columns) used in the search tool

	A	E	F	G	H	I
1	Title	Lésion élémentaire	Couleur	Taille	Douloureux	Signes généraux
2	hyperlinkType(D)	csvFilter	csvFilter	csvFilter	csvFilter	csvFilter
3	Aphthose commune	Erosion, Ulcération	blanc, rouge, gris, jaunâtre	moins de 3 mm, moins de 3 mm	oui	absents, dysphagie
4	Botryomycome	Nodule, Masse	rouge, jaunâtre, blanc	moins d'1 cm, 1 à 3 cm	non	absents
5	Candidose	Plaque, Erythème, Kératose	rouge, blanc, blanc jaunâtre	moins de 3 mm, moins de 3 mm	oui, non	absents, sensation de brûlure
6	Diapneusie	Nodule, Masse	rose, blanc, rouge	moins de 3 mm, moins de 3 mm	non, oui	absents
7	Epulis	Nodule, Masse	rouge, rose	moins de 3 mm, moins de 3 mm	non	absents
8	Granulations de Fordyce	Papule, Nodule	blanc, blanc jaunâtre, jaunâtre	moins de 3 mm	non	absents
9	Herpès récurrent	Erythème, Vésicule, Erosion	rouge, jaunâtre, gris, blanc	moins de 3 mm, moins de 3 mm	oui, non	absents, fièvre, atteinte générale
10	Hypertrophie des papilles caliciformes	Hypertrophie papillaire, Nodule	rose, rouge	moins de 3 mm, moins de 3 mm	non	absents
11	Hypertrophie des papilles foliées	Hypertrophie papillaire, Nodule	rose, rouge	moins de 3 mm, moins de 3 mm	non	absents
12	Hypertrophie des papilles fongiformes	Hypertrophie papillaire, Nodule	rouge	moins de 3 mm	non, oui	absents, sensation de brûlure
13	Langue fissurée, scrotale ou plicaturée	Fissure	rouge, rose	moins d'1 cm, 1 à 3 cm	non	absents
14	Langue géographique	Dépapillation, Plaque, Erythème, Kératose	blanc, blanc jaunâtre, jaunâtre	moins d'1 cm, 1 à 3 cm	non	absents, sensation de brûlure
15	Langue saburrale	Plaque, Kératose	blanc, gris, blanc jaunâtre	1 à 3 cm, plus de 3 cm	non	absents, xérostomie
16	Langue vilieuse ou chevelue	Hypertrophie papillaire, Plaque	jaunâtre, orangé, brun, blanc	1 à 3 cm, plus de 3 cm	non	absents
17	Leucoplasie tabagique	Papule, Masse, Kératose	blanc, gris	moins de 3 mm, moins de 3 mm	non	absents
18	Lichen évolutif érosif	Erosion, Plaque	rouge	moins de 3 mm, moins de 3 mm	oui	xérostomie, sensation de brûlure
19	Lichen plan buccal	Kératose, Plaque, Papule	blanc	moins de 3 mm, moins de 3 mm	oui, non	manifestations cutanées
20	Lipome	Masse	jaunâtre	moins d'1 cm, 1 à 3 cm	non	absents

Figure 1 : Extract from the table listing the criteria for each lesion (screenshot)

Thirdly, clinical sheets were written. They all follow the same outline: Definition, Etiologies - Risk factors - Frequency, Clinical signs, Localization, Differential diagnosis, Additional tests, Evolution, Medical care, and Bibliography. Most of the information comes from books and oral dermatological atlases. Clinical sheets were then completed thanks to articles found with the scientific publications search tool PubMed [7], and Orphanet [8], an official website created by the French institute INSERM (Institut National de la Santé et de la Recherche Médicale) dealing with rare or genetic diseases. This website follows several international quality charts: HONcode (Health On the Net code), eHealth Code of Ethics, 'Guidelines for Medical and Health Information Sites on the Internet' of the American Medical Association, recommendations from National Council of French Doctors, and from the Haute Autorité de Santé (French High Authority of Health). A specific bibliography was included in every clinical sheet using the tool Zotero [9]. A general bibliography, including the common sources, is also available.

Finally, exceptional pathologies were excluded. In fact, these cases increased the list of possible diagnoses despite the low risk of being the right diagnosis. They were more a source of confusion than solutions to consider. Pathologies that were not well documented were also excluded. The lack of studies shows a low rate of occurrence. It was hard to define clinical manifestations and to consider them as real diagnostic possibilities. Finally, we excluded pathologies with no clinical mouth signs detectable at the examination. So the following pathologies were excluded: atrophic bullosa epidermolysis, xeroderma pigmentosum, giant cell fibroma, neurinoma, Cowden's disease, Sweet disease, basocellular carcinoma, Kawasaki's disease, benign fibrous histiocytoma, tuberous sclerosis, salivary cysts, hyalinosis cutis and mucosae, staphylococcus infection.

To simplify the search tool, all exceptional variations of pathologies were not included when diagnostic criteria were assigned. These variations are however mentioned in clinical sheets.

At last, lesions were illustrated. At the end of this inventory, 144 pathologies were included. Most of the photography's were provided by Dr. Gérard Bader. The rest was given by other odontology-stomatology and dermatology teachers and physicians in University Hospitals.

### Building the website

The tool was designed on a website to facilitate its use and its spreading. It was created on Word press [10], a simple

platform which does not require computer coding. OVH (Oles Van Herman) [11] society hosts the website. We acquired the domain name [outil-diagnostic-dermato-buccale.fr](http://outil-diagnostic-dermato-buccale.fr).

A system allowing to sort lesions using diagnostic criteria was required in a way that the physician could make his diagnosis in front of an oral dermatological lesion.

The tool Awesome Table [12] was used to design the research tool with drop-down menus. This is a Google software, generating presentation sheets from Google Sheets files.

The first sheet (Figure 2) represents the database and has a table form. Lines correspond to lesions, columns correspond to categories of diagnostic criteria. There are also columns for Description and Picture to make a thumbnail of each lesion, and another one with a link to clinical sheets.

The second sheet is written in JavaScript code and controls the tool's appearance and formatting.

Once the presentation is done on Awesome Table (Figure 3), a short Java Script code can be generated and included in a website.

### Website's formatting

Word press allows to build a customized sitemap from an existing theme. Design elements are already defined depending of the chosen theme.

Because the tool search is the main element of the website, it is positioned on the home page.

The menu bar (Figure 4) leads to several pages. "Recherche", corresponding to the home page.

"Fiches lésionnelles", containing the alphabetic list of lesions, linked to clinical sheets. "Guide des lésions élémentaires", which is a lexic of elementary lesions used in the search tool. It was created to remind definitions and vocabulary and avoid user's misunderstanding. "Démarche diagnostique" recapitulates the elements to consider to obtain the best diagnosis possible.

	A	B	C	D	E	F
22	Langue saburrale	Langue caractérisée par la présence d'un end	<a href="http://outil.diagnosticdermatobuccale.ovh/wp-co">http://outil.diagnosticdermatobuccale.ovh/wp-co</a>	<a href="http://outil.diagnosticdermatobuccale.ovh/index.php">http://outil.diagnosticdermatobuccale.ovh/index.php</a>	Plaques, Kératose	blanc, gris, blanc jaun
23	Langue villosité ou chevelue	Affection fréquente marquée par une colorati	<a href="http://outil.diagnosticdermatobuccale.ovh/wp-co">http://outil.diagnosticdermatobuccale.ovh/wp-co</a>	<a href="http://outil.diagnosticdermatobuccale.ovh/index.php">http://outil.diagnosticdermatobuccale.ovh/index.php</a>	Hypertrophie papillaire,	jaunâtre, orangé, brun
24	Leucoplasie tabagique ou idiopati	La leucoplasie est la formation d'une zone bla	<a href="http://outil.diagnosticdermatobuccale.ovh/wp-co">http://outil.diagnosticdermatobuccale.ovh/wp-co</a>	<a href="http://outil.diagnosticdermatobuccale.ovh/index.php">http://outil.diagnosticdermatobuccale.ovh/index.php</a>	Papule, Kératose, Pla	blanc, gris
25	Lichen érythémateux érosif	Dermatose cutanéomuqueuse inflammatoire	<a href="http://outil.diagnosticdermatobuccale.ovh/wp-co">http://outil.diagnosticdermatobuccale.ovh/wp-co</a>	<a href="http://outil.diagnosticdermatobuccale.ovh/index.php">http://outil.diagnosticdermatobuccale.ovh/index.php</a>	Erosion, Plaque	rouge
26	Lichen plan buccal	Dermatose cutanéomuqueuse inflammatoire	<a href="http://outil.diagnosticdermatobuccale.ovh/wp-co">http://outil.diagnosticdermatobuccale.ovh/wp-co</a>	<a href="http://outil.diagnosticdermatobuccale.ovh/wp-admin">http://outil.diagnosticdermatobuccale.ovh/wp-admin</a>	Kératose, Plaque, Papu	blanc, brun, noir
27	Lines alba	Variation anatomique normale de la muqueus	<a href="http://outil.diagnosticdermatobuccale.ovh/wp-co">http://outil.diagnosticdermatobuccale.ovh/wp-co</a>	<a href="http://outil.diagnosticdermatobuccale.ovh/index.php">http://outil.diagnosticdermatobuccale.ovh/index.php</a>	Kératose, Hypertrophie	rose, blanc
28	Lipome	Tumeur bénigne constituée par du tissu adipe	<a href="http://outil.diagnosticdermatobuccale.ovh/wp-co">http://outil.diagnosticdermatobuccale.ovh/wp-co</a>	<a href="http://outil.diagnosticdermatobuccale.ovh/index.php">http://outil.diagnosticdermatobuccale.ovh/index.php</a>	Masse	jaunâtre, blanc jaunâtre
29	Lithase salivaire	Atteinte calculeuse d'une glande salivaire.	<a href="http://outil.diagnosticdermatobuccale.ovh/wp-co">http://outil.diagnosticdermatobuccale.ovh/wp-co</a>	<a href="http://outil.diagnosticdermatobuccale.ovh/index.php">http://outil.diagnosticdermatobuccale.ovh/index.php</a>	Tuméfaction	rose, rouge
30	Muccocèle	Aussi appelé Pseudokyste salivaire. C'est une	<a href="http://outil.diagnosticdermatobuccale.ovh/wp-co">http://outil.diagnosticdermatobuccale.ovh/wp-co</a>	<a href="http://outil.diagnosticdermatobuccale.ovh/index.php">http://outil.diagnosticdermatobuccale.ovh/index.php</a>	Masse, Vésicule, Bulle	rouge, rose, violacé
31	Perleche/ Chéilite	Infection à Candida Albicans touchant les lèvr	<a href="http://outil.diagnosticdermatobuccale.ovh/wp-co">http://outil.diagnosticdermatobuccale.ovh/wp-co</a>	<a href="http://outil.diagnosticdermatobuccale.ovh/index.php">http://outil.diagnosticdermatobuccale.ovh/index.php</a>	Croûte, Plaque, Erosion	rouge, blanc jaunâtre,
32	Primo-infection herpétique	Infection virale fréquente de la muqueuse buc	<a href="http://outil.diagnosticdermatobuccale.ovh/wp-co">http://outil.diagnosticdermatobuccale.ovh/wp-co</a>	<a href="http://outil.diagnosticdermatobuccale.ovh/index.php">http://outil.diagnosticdermatobuccale.ovh/index.php</a>	Erythème, Ulcération, E	rouge, blanc jaunâtre,
33	Stomatite nicotinique	Kératose localisée sur le palais et liée au tab	<a href="http://outil.diagnosticdermatobuccale.ovh/wp-co">http://outil.diagnosticdermatobuccale.ovh/wp-co</a>	<a href="http://outil.diagnosticdermatobuccale.ovh/index.php">http://outil.diagnosticdermatobuccale.ovh/index.php</a>	Erosion, Papule	rouge, blanc, gris
34	Tatouage à l'amalgame	Coloration de la gencive par diffusion des pig	<a href="http://outil.diagnosticdermatobuccale.ovh/wp-co">http://outil.diagnosticdermatobuccale.ovh/wp-co</a>	<a href="http://outil.diagnosticdermatobuccale.ovh/index.php">http://outil.diagnosticdermatobuccale.ovh/index.php</a>	Plaques, Macule	noir, gris, bleuâtre
35	Torus/ Exostose	Excroissance osseuse non pathologique	<a href="http://outil.diagnosticdermatobuccale.ovh/wp-co">http://outil.diagnosticdermatobuccale.ovh/wp-co</a>	<a href="http://outil.diagnosticdermatobuccale.ovh/index.php">http://outil.diagnosticdermatobuccale.ovh/index.php</a>	Masse, Nodule	rose
36	Tumeur d'Abrikossoff	Aussi appelée Tumeur à cellules granuleuses	<a href="http://outil.diagnosticdermatobuccale.ovh/wp-co">http://outil.diagnosticdermatobuccale.ovh/wp-co</a>	<a href="http://outil.diagnosticdermatobuccale.ovh/index.php">http://outil.diagnosticdermatobuccale.ovh/index.php</a>	Masse, Nodule	rose, blanc, jaunâtre
37	Ulcère traumatique	Lésion ulcéraire causée par une irritation mé	<a href="http://outil.diagnosticdermatobuccale.ovh/wp-co">http://outil.diagnosticdermatobuccale.ovh/wp-co</a>	<a href="http://outil.diagnosticdermatobuccale.ovh/index.php">http://outil.diagnosticdermatobuccale.ovh/index.php</a>	Ulcération	blanc, rouge, gris, jaun
38	Varices sublinguales	Variation physiologique fréquente de la langu	<a href="https://2.wp.com/outil.diagnosticdermatobuccal">https://2.wp.com/outil.diagnosticdermatobuccal</a>	<a href="http://outil.diagnosticdermatobuccale.ovh/index.php">http://outil.diagnosticdermatobuccale.ovh/index.php</a>	Plaques, Tuméfaction	violacé, bleuâtre, rouge
39	Vernus vulgaire	Lésion bénigne fréquente chez l'enfant.	<a href="http://outil.diagnosticdermatobuccale.ovh/wp-co">http://outil.diagnosticdermatobuccale.ovh/wp-co</a>	<a href="http://outil.diagnosticdermatobuccale.ovh/index.php">http://outil.diagnosticdermatobuccale.ovh/index.php</a>	Papule, Nodule	blanc
40	Xérostomie	Sécheresse buccale associée à une diminitu	<a href="http://outil.diagnosticdermatobuccale.ovh/wp-co">http://outil.diagnosticdermatobuccale.ovh/wp-co</a>	<a href="http://outil.diagnosticdermatobuccale.ovh/index.php">http://outil.diagnosticdermatobuccale.ovh/index.php</a>	Atrophie, Dépapillation	rose, rouge
41	Adénocarcinome	Tumeur maligne des glandes salivaires. Peut	<a href="http://outil.diagnosticdermatobuccale.ovh/wp-co">http://outil.diagnosticdermatobuccale.ovh/wp-co</a>	<a href="http://outil.diagnosticdermatobuccale.ovh/index.php">http://outil.diagnosticdermatobuccale.ovh/index.php</a>	Masse, Ulcération	rose, rouge
42	Adénome pléomorphe	Tumeur bénigne des glandes salivaires.	<a href="http://outil.diagnosticdermatobuccale.ovh/wp-co">http://outil.diagnosticdermatobuccale.ovh/wp-co</a>	<a href="http://outil.diagnosticdermatobuccale.ovh/index.php">http://outil.diagnosticdermatobuccale.ovh/index.php</a>	Masse	rose

Figure 2 : Database necessary for the search tool (screenshot)

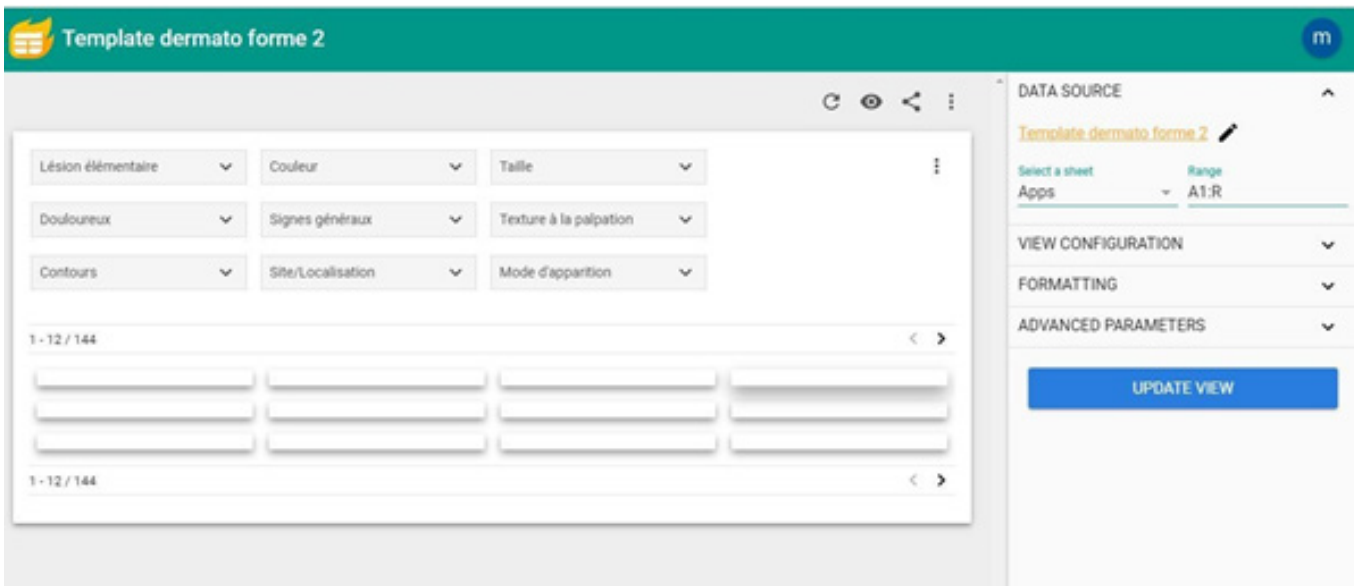


Figure 3 : Presentation on <https://awesome-table.com/> (screenshot)

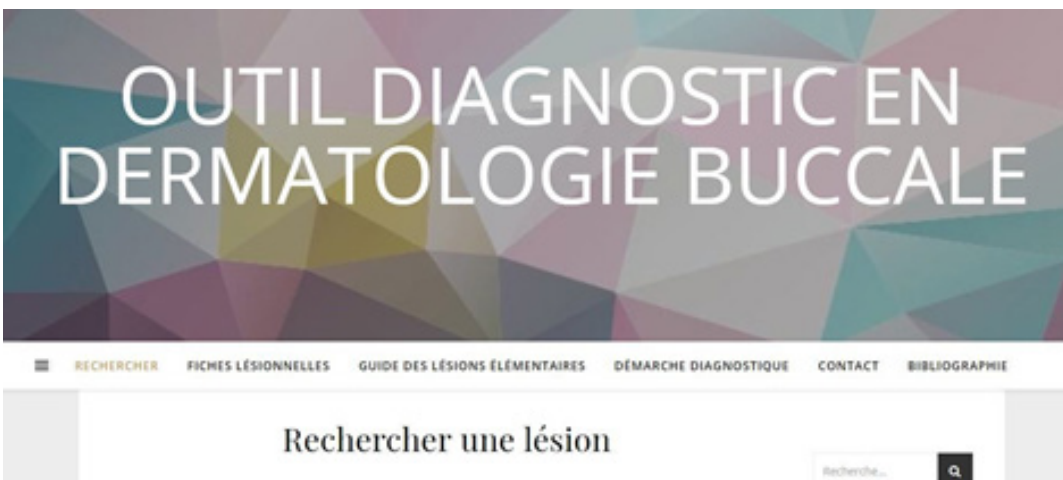

Figure 4 : Menu bar on the website's home page (screenshot).

A "Contact" page was made to collect opinions, questions, advice, and user's feedback. "Bibliography" gathers the main books and websites used, and also pictures credits. A specific bibliography is available for each clinical sheet.

A search bar was also included in the side menu. It permits to search terms in the whole content of the website.

Word press proposes to add "tags" to lesions' articles. In this website, tags were assigned to general risk factors, which were willingly excluded from the research criteria. Tags are referring terms like "tobacco" or "immunodepression".

Tags are located in the side menu on the home page. Users can click on one of the tags, and a list of the clinical sheets linked to the risk factor appears.

## Results presentation

When the research starts, there are 144 pathologies on the home page. Users select one or several criteria. Only results corresponding to the selected criteria appear. The more criteria are selected, the more precise the research is. Photographs are also useful to guide the diagnosis.

Even if the research leads to several results, the user can consult the clinical sheets to find complementary information for his diagnosis.

If there are no results at all after the selection of criteria, the user should remove one or several criteria and refer to clinical sheets to find a diagnosis.

## Test phase

The website was released on the 1st of April 2019. We first tested the website inside the dental clinic of the University of Rennes 1. It represents a sample of 300 students and teachers. Communication was made by the internal e-mail service of the University, social networks and paper notices in the clinic.

## Discussion

First of all, it's important to remind that this tool is only an aid to diagnose and does not replace specialists' knowledge and skills.

Moreover, it is not possible to include the patient's history for the research on the website. Every diagnosis must have an anamnesis and a rigorous clinical examination.

Because the tool is a website, it is easy to often update information. Scientific data, especially in diagnosis and treatment, are always evolving. It is important to keep the information up to date.

The evaluation of the website is based on frequentation and feedbacks. As the policy of confidentiality specifies it, there is no data recovery. We used Word press's tool Jetpack [13] to count visits on the website pages. The number of times that the research page has been generated is known but the number of researches made, their results or the terms selected are not.

If the research doesn't go well, the user has the possibility to report it via a contact form.

## What is the interest compared to an atlas of dermatology?

This tool follows a reverse diagnostic procedure of an oral dermatological atlas. Atlases contain very complete information on pathologies. But to search for a lesion in an atlas, the physician should already have a diagnostic hypothesis.

The research through the website is interesting when there is no hypothesis at the start.

With this tool, the physician has to describe what he sees, deduce diagnostic criteria and enter them in the drop-down menus. Compared to classical atlases, it offers the possibility to sort pathologies. Depending on criteria selection, pathologies are proposed. It does not demand a diagnostic hypothesis.

## Conclusion

Searching for a lesion with this tool is fast and easy. After the first test phase, it has been broadcast on social networks. Since its release in April 2019, more than 3400 visitors have visited the website and more than 9300 researches have been done.

The website is daily visited. The more the tool is used, the more efficient it becomes thanks to feedbacks.

## References

1. Roume M, Azogui-Levy S, Lescaille G, Descroix V, Rochefort J (2019) Knowledge and practices of dentists in France regarding oral mucosal diseases: a national survey. *J Oral Med Oral Surg* 25:10.
2. Delebarre H (2017) Aide for the diagnosis of nodular injuries of the woman who is orally based on clinical criteria: clinics and the creation of an internet site.
3. Kuffer R, Lombardi T, Husson-Bui C, Courrier B, Samson J (2009) *La Muqueuse Buccale de la clinic et traitement*, Med'Com Edition.
4. Laskaris G (2017) *Color Atlas of Oral Diseases: Diagnosis and Treatment*. Thieme 710 p.
5. Regezi, Sciubba, Jordan (2017) *Oral Pathology, Clinical pathologic correlations, 7e édition*.
6. Szpirglas H, Slama LB (1999) *Pathology of the muqueuse buccale*.
7. Home - PubMed - NCBI [Internet]. [quoted on 31.05.2019]. Available on: <https://www.ncbi.nlm.nih.gov/pubmed/>
8. Orphanet [Internet]. [quoted on 31.05.2019]. Available on: <http://www.orpha.net/consor/www/cgi-bin/index.php?lng=FR>
9. Zotero [Internet]. [quoted on 31.05.2019]. Available on: <https://www.zotero.org/>
10. WordPress.com [Internet]. WordPress.com. [quoted on 31.05.2019]. Available on: <https://fr.wordpress.com/>
11. Hébergement Internet, Cloud, et Serveurs dédiés [Internet]. [quoted on 31.05.2019]. Available on : <https://www.ovh.com/fr/>
12. Awesome Table [Internet]. [quoted on 31.05.19]. Available on: <https://awesome-table.com/>
13. Jetpack [Internet]. Jetpack — Essential Security & Performance for WordPress. 2017 [quoted on 18.10.2019]

### Submit your manuscript to a JScholar journal and benefit from:

- ☞ Convenient online submission
- ☞ Rigorous peer review
- ☞ Immediate publication on acceptance
- ☞ Open access: articles freely available online
- ☞ High visibility within the field
- ☞ Better discount for your subsequent articles

Submit your manuscript at  
<http://www.jscholaronline.org/submit-manuscript.php>