

Presence of HPV in Oral Lesions and Its Relation with Tumor Suppressor Genes in the Way to Find New Strategies to Prevent Oral Cancer

Azúa-Romeo Javier M.D., Ph.D., M.Ed^{1,*}, Simon Angela M.D², Moreno-Loshuertos Raquel BD, PhD³

¹Professor of Histology, Department of Anatomy and Histology, University of Zaragoza

²Pre-doctoral student, Department of Anatomy and Histology, University of Zaragoza

³Professor of Biology, Department of Biochemistry and Molecular and Cellular Biology, The University of Zaragoza

*Corresponding author: Azúa-Romeo, Javier M.D., Ph.D., M.Ed, Department of Anatomy and Histology, University of Zaragoza, C/ Domingo Miral s/n, Zaragoza (5009), Spain, Tel: +34667503270; Email: jazua@unizar.es

Received Date: August 13, 2019 Accepted Date: September 15, 2019 Published Date: September 17, 2019

Citation: Azúa-Romeo, Javier (2019) Presence of HPV in Oral Lesions and Its Relation with Tumor Suppressor Genes in the Way to Find New Strategies to Prevent Oral Cancer. J Dent Oral Health 6: 1-8.

Abstract

Objectives: The oral infection by human papillomavirus (HPV) is considered a direct cause of squamous cell carcinomas of the oral cavity and oropharynx. The aim of this study was to demonstrate the correlation between HPV infection and the oncogenic progression of oral lesions and to assess the tumor regulation mechanisms that are activated following infection.

Material and methods: a histological and immunohistochemical study of 50 selected samples from our files was conducted, in which the expression of the adhesion protein E-cadherin, the proliferation marker Ki67, the tumor suppressor proteins p16 and p21 and the tumor suppressor gene p53 were assessed.

Results: HPV infection causes changes in the normal cell cycle of infected tissue and cytological changes. Through its mitogenic power that increases cell activity and activates cellular proliferation. The p53 tumor suppressor gene activates the p21 tumor inhibitory protein. Overexpression of tumor inhibitory p16 occurs simultaneously with p21 overexpression.

Conclusion: The results support previous studies showing that HPV has mitogenic power and its presence activates cell mechanisms that control cell proliferation and inhibit progression to cancer. p16ink4a determined by immunohistochemistry allows differentiating high or low-risk lesions.

We believe in the benefits of oral HPV type screening and vaccination.

Article Summary:

Strengths and limitations of this study:

- Our sample size, although adequate, would be desirable to be larger
- The results showed to be statistically representative
- The use of immunohistochemistry in order to detect the presence of HPV in the oral tissues has shown to be really an accurate and non-expensive suitable method

Keywords: Human papillomavirus; HPV; squamous carcinoma; oral cavity; oropharynx; p16; p21; Ki67; p53; E-cadherin.

Introduction

Cancer of the oral cavity and oropharynx is the 11th most common cancer worldwide [1]. 25-35% of cases are believed to be associated with HPV, specifically palatine tonsils and the base of the tongue [2]. The incidence has increased in the last 30 years [2], which could be due to the effects of HPV. In 2007, the International Centre for Cancer Research estimated that 31% of squamous cancers of the oral cavity and oropharynx are attributable to HPV16; this number increases to 39% in western and northern Europe [3]. However, a distinction should be made between different regions, as in southern Europe fewer than 20% are HPV related, but in North America, 60% are HPV associated [4].

HPV is a small-sized epitheliotropic double-stranded DNA virus [5] and is composed of a protein capsid in which the genome of double-stranded nucleic acid can be found. It has no wrapping [5]. The early region is composed of the E (early) genes. Six early genes are known: E1, E2, E4, E5, E6, and E7. The late region is composed of the L (late) genes. Two late genes are known: L1 and L2. They are expressed in the late stages of the viral cycle and their function is to encode the structural proteins that form the capsid.

Approximately 30 types of HPV infect mucous membranes, whether nasopharyngeal, oral or genital [6]. These viruses are divided into three other groups according to their neoplastic potential: high, intermediate and low risk [4]. The genotypes considered to be of low risk are 2, 6, 11, 13, 43, 44 and 48; those of intermediate-risk are 31, 33, 35, 50, 51, 52; those of high risk are 16, 18, 45 and 59. Genotypes 16 and 18 are the most common high-risk subtypes and are related to precancerous and cancerous lesions [7]. It should be noted that the oncogenic potential of each genotype varies, despite expressing the same oncoproteins [8]. The most common low-risk subtypes are 6 and 11 [9].

The genotypes that are related to oral lesions are 1, 2, 3, 4, 6, 7, 10, 11, 13, 16, 18, 31, 32, 33, 35 and 57. Subtypes 13 and 32 are exclusive to the oral cavity [4].

In high-risk HPV16 and HPV18 types, E6 and E7 proteins can induce immortalisation of keratinocytes, which is partly due to the interaction of HPV16 E7 with certain proteins, especially pRB (the product of the retinoblastoma gene) which plays an essential role in the control of the cell cycle since it regulates the activity of various transcription factors (E2F) [10].

The cell cycle control is mediated by a small group of proteins, including the tumor suppressor protein p16ink4a,

which binds to CDKs and inhibits their kinase activity (inhibitors of cyclin-dependent kinases; CDKI). Therefore, ectopic expression of p16ink4a leads to the accumulation of hypophosphorylated Rb, sequestration of E2F and consequently arrest of G1. The Rb protein imposes negative control on p16, so the functional inactivation of pRb by any means leads to the overexpression of p16 and therefore to the activation of the p16/cyclin D/CDK4/regulatory pRb cascade of the cell cycle [11].

The interaction of HPV16 E7 with pRb causes the release of active E2F and stimulation of S-phase entry, even in the absence of active CDK4 and CDK6 complexes and in the presence of high levels of p16ink4a, which indicates that the suppressor function of p16 can be overcome by viral oncogenes. Thus, the overexpression of p16 that would have stopped the cell cycle under normal conditions has no effect, since pRb has been previously blocked by E7.

Inactivation of p16 regulatory function is seen in the very early stages of the oncogenic progression of HPV, but not during late malignant transformation, whereas the expression of E6/E7 has only been confirmed by in situ hybridization in severe dysplasia or oral carcinoma [12].

p16ink4a [11] can be demonstrated immunohistochemically, showing a different staining pattern depending on the infection due to high or low-risk genotypes, regardless of the type of epithelial lesion.

The efficacy of p16 immunostaining is beyond doubt [13,14], considering that in the basal state, it is not expressed in non-dysplastic cells. Almost 100% of squamous cell carcinomas and severe epithelial dysplasia associated with HPV AR overexpress p16 diffusely, although not all cases that show overexpression of p16 are HPV positive. It indicates that there are unknown pathways of activation independent to HPV. Negative or weakly immunostaining has been described in adenocarcinomas not associated with HPV, suggesting that the dysregulation of this protein may be related in their etiology.

Material and Methods

50 samples were randomly selected, without knowing their diagnosis. All of them were histologically and immunohistochemically analyzed providing a diagnosis based on the expression of the following parameters: p16, Ki67, p21, p53, and E-cadherin. Finally, it was found to include 17 benign, 21 premalignant and 12 malignant lesions (Table 1).

		Frequency	Percentage
Diagnosis	Benign	17	34
	Premalignant	21	42
	Malignant	12	24
	Total	50	100

Table 1: Percentage and frequency of the histological diagnosis

The relationship between head and neck squamous cell cancer and HPV was described in 1985 [15] nowadays there is a classification relating to HPV presence [7].

Class I: No overexpressed p16, negative for HPV. Conventional head and neck cancer without evidence of HPV infection. p16 is inactivated and mutations of p53 are absent.

Class II: p16 negative and positive for HPV. Conventional cancer that acquired infection later, so it does not express p16.

Class III: Overexpresses p16 and HPV positive. This one has the highest viral load, nevertheless, survival at 5 years is 79%.

Class IV: Over expresses p16 but negative for HPV. These tumors represent a small percentage and may arise for two reasons: overexpression of p16 is due to other routes or by another infectious agent, or it is a misclassification as being negative due to insufficient sensitivity of the test performed.

HPV negative tumors that overexpress p16 have a better prognosis than those that do not overexpress p16. Ki67 is present during all active phases of the cell cycle and is absent during the resting phase. The p21 tumor suppressor protein also stops the cell in the G1 phase [16] overexpression indicates the uncontrolled division of cells. p53 tumor suppressor gene repairs damaged DNA, stopping the cell in the G1 phase, and induces the activation of p21. Its overexpression indicates cell damage. E-cadherin is involved in cell adhesion and the maintenance of cell polarity, integrity, and morphology in epithelial tissues.

Patient and Public Involvement

This study has been carried out on paraffin blocks

stored in our institution, without causing any type of damage to the tissue studied. Each patient, before being operated on, compulsorily signs an informed consent for the possible application of their tissue for research purposes, without prejudice to the diagnosis, which is the fundamental objective of the biopsy. Once our study was completed, a complementary report was attached to the initial pathological report, which is sent to the doctor in charge of each patient to inform them of the result.

Following the World Medical Association Declaration of Helsinki Ethical Principles for Medical Research Involving Human Subjects, adopted at the 64th WMA General Assembly, Fortaleza, Brazil, October 2013, this project does not need to be reviewed by the Ethical Committee of our Institution, as far as it should have attached the patients consent form and those are available for public consultation.

Once all these variables had been assessed, the data were arranged in table 2.

Immunohistochemical assay

Several slides with 4 µm-thick sections from the tissue blocks were prepared. Subsequently, dewaxing and rehydration were carried out through 4 baths of xylol 100% followed by 3 baths of absolute alcohol. Antigen unmasking was carried out in a pressure cooker with citrate buffer at pH6, then slides were washed with running water for three minutes. The slides were then washed with distilled water and PBS(Phosphate buffered saline). The immunohistochemical labeling technique was carried out in an Optimax Plus automatic immune team from (Menarini Diagnostics, UK). The amplified biotin/streptavidin (BSA) technique was used as a supersensitive immunodetection method of (Biogenex, USA).

The following antibodies were used (DAKO Cytomation, USA): p16INK4a (clone E6H4), p21 (clone DCS-60.2), p53 (clone DO-7) and Ki67 (clone PP-67).

Sano et al. [4] established a classification according to the percentage of positive cells for p16, which we used also to assess p21 staining:

- 0 to 5%: negative
- <80%: focal positive
- >80%: diffuse positive

No immunoreactivity was detected in non-dysplastic epithelium, mesenchymal or metaplastic cells, although some

Nº	Case	Diagnosis	Ki67	P16	P21	P53	e-cadherin	Gender
1	7353	Benign	YES	YES	YES	NO	+++	F
2	25654	Benign	NO	NO	NO	NO	+++	F
3	8100	Benign	YES	NO	YES	NO	+++	M
4	101	Benign	YES	NO	YES	NO	+++	M
5	289	Benign	NO	NO	NO	NO	+++	F
6	324	Benign	YES	NO	NO	NO	+++	F
7	351	Benign	NO	NO	NO	NO	+++	F
8	500	Benign	NO	NO	NO	NO	+++	F
9	564	Benign	YES	YES	NO	NO	+++	F
10	808	Benign	YES	NO	NO	NO	+++	M
11	809	Benign	YES	NO	NO	NO	+++	M
12	9732	Benign	YES	NO	NO	NO	+++	F
13	10197	Premalign	YES	NO	NO	NO	+++	F
14	10219	Premalign	YES	NO	YES	NO	+++	F
15	10278	Premalign	YES	NO	NO	NO	+++	F
16	28875	Premalign	YES	YES	YES	YES	+++	F
17	3296	Premalign	YES	NO	NO	NO	+++	F
18	1619	Premalign	YES	YES	NO	NO	+++	M
19	6313	Premalign	YES	YES	YES	YES	+++	F
20	6513	Premalign	YES	YES	YES	NO	+++	M
21	9196	Premalign	NO	YES	NO	NO	+++	M
22	174	Premalign	NO	NO	NO	NO	+++	F
23	2635	Premalign	NO	NO	NO	NO	+++	M
24	2857	Premalign	YES	NO	NO	NO	+++	M
25	6426	Premalign	YES	NO	NO	NO	+++	F
26	9740	Premalign	YES	NO	NO	NO	+++	M
27	23143	Premalign	YES	YES	NO	NO	+++	M
28	23144	Premalign	YES	NO	YES	NO	+++	F
29	1623	Premalign	YES	NO	NO	NO	+++	F
30	4729	Premalign	NO	NO	NO	NO	+++	F
31	9733	Premalign	YES	NO	YES	NO	+++	M
32	23096	Premalign	YES	YES	YES	NO	+++	M
33	23865	Premalign	NO	NO	NO	NO	+++	M
34	4839	Malignant	NO	NO	NO	NO	+++	F
35	8973	Malignant	NO	YES	NO	YES	+++	F
36	5147	Malignant	YES	YES	YES	YES	+++	F
37	7542	Malignant	YES	NO	NO	YES	+++	M
38	8821	Malignant	YES	NO	NO	YES	+++	F
39	1445	Malignant	YES	NO	NO	NO	+++	M
40	2403	Malignant	YES	YES	YES	NO	+++	F
41	4466	Malignant	YES	YES	NO	NO	+++	F
42	7946	Malignant	YES	NO	YES	YES	+++	M
43	23145	Malignant	YES	NO	YES	NO	+++	F
44	2397	Malignant	YES	YES	YES	NO	+++	F
45	5374	Malignant	YES	YES	YES	NO	+++	F
46	6099	Malignant	YES	NO	YES	YES	+++	F
47	6688	Malignant	YES	YES	YES	YES	+++	F
48	6948	Malignant	YES	NO	NO	NO	+++	F
49	8335	Malignant	YES	NO	YES	YES	+++	M
50	8870	Malignant	YES	NO	YES	YES	+++	M

Table 2: Immunohistochemical and histological results, referring each case. F=female; M=male

weak reactivity was found in the cytoplasm and nuclei of proliferating fibroblasts, endothelial cells, and some inflammatory cells.

All samples have been tested with HC2 high-risk RNA. The HC2 probes detect 13 high-risk genotypes. The test was done per package insert. Three negative controls, one low-risk HPV, one high-risk HPV, and three positive calibrators were included in each assay run.

Statistical assessment

We aimed to find a statistically significant relationship between the analyzed variables. Seven variables were assessed, two quantitative (Ki67 and p53) and five qualitative (sex, diagnosis, p16, p21, and E-cadherin). E-cadherin provided positive results in all cases, thus was excluded from the study.

We studied the distribution of the two quantitative variables (Ki67 and p53) through the Kolmogorov-Smirnov test, under the null hypothesis of normality.

To assess differences between the means of the quantitative variables with respect to the other variables and after knowing that their distributions did not conform to normality, we used the Mann-Whitney U test.

Given that the main objective of the study was to find a relationship of dependence between the oncoprotein p16 and the other variables, we performed a conversion to be able to apply the chi-squared test for dichotomous qualitative variables.

Subsequently, we performed a bivariate analysis of the hypothesis with the chi-squared test under the null hypothesis of independence.

Results

The histological diagnosis was made following the WHO histological classification; however, we summarized them in three groups, as seen in Table I, to facilitate understanding: benign, premalignant and malignant.

The immunohistochemical study, showed positive staining for p16, p21, and p53 in most malignant lesions, as well as several premalignant and benign lesions. The proliferative marker Ki67 was stronger in malignant lesions and in biologically active benign lesions, such as leucoplasia. E-cadherin staining was positive in all the cases (Table 2).

Diagnosis presented a clear relationship of dependence

with Ki67 and p53, which agrees with what was already known. Cells of malignant tissues undergo uncontrolled division however, cells of benign lesions have a proliferation index similar to normal tissues.

A relationship of dependence of p21 protein with p16, p53 and Ki67 was also found. The relationship between p21 and p53 was clear since p53 can activate p21. The relationship between p21 and Ki67 can also be explained since the function of p21 is to inhibit the uncontrolled proliferation of cells by stopping them in the G1 phase; therefore, an increase in the cell proliferation index will lead to overexpression of p21 as shown in Table 3.

We found positive staining for p16 in both malignant and benign lesions, but when we analyzed the relationship between p16 and p21, the p-value was <0.05 , so we rejected the null hypothesis of independence of the variables and accepted the alternative dependency hypothesis, which means there is a relationship between p16 and p21.

The overexpression of p16 (Figure 1) related to the histological diagnosis showed a wide distribution, with considerable presence of p16 in benign lesions.

We found completely overall concordance and positive concordance rates between p16 ink4a immunostaining and Hybrid Capture² High-Risk HPV DNA Test™ (hc2) assays.

Discussion

The study raised several questions: is it possible that the practice of orogenital sex with a person infected with the virus could result in infection and oral cancer? Would the general incidence of this cancer decrease if population screening of oral infection by HPV was carried out and a campaign of vaccination against these serotypes with a tendency to infect this tissue? Would it help if the male population was included in the screening and vaccination guidelines, assessing both genital and oral tissue?

After carrying out this study and interpreting the results, we can confirm that the presence of actively replicating virus activates a series of tumor inhibitory proteins whose objective is to stop the uncontrolled cell division that can lead to cancer.

Specifying and referring to the dependency relationships found among different proteins, we found the following:

Contingency Table					
			Diagnosis		Total
			Benign	Malignant	
p16	No overexpression	Count	24	10	34
		p16 %	70,6%	29,4%	100%
	Overexpression	Count	9	7	16
		p16 %	56,3%	43,8%	100%
Total		Count	33	17	50
		p16 %	66%	34%	100%

Table 3: contingency table for protein p16.

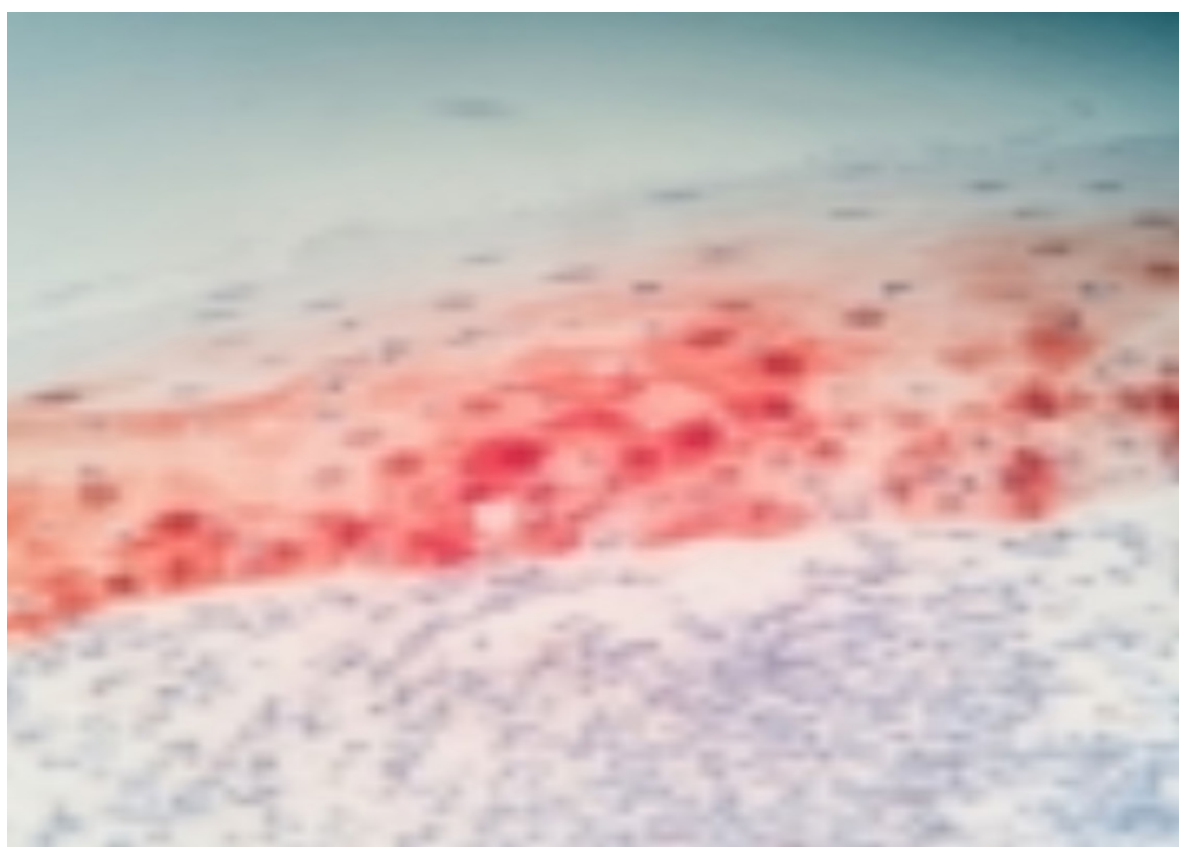


Figure 1

The diagnosis presents a clear relationship of dependence with the proteins Ki67 and p53, which supports previous studies. Cells that suffer from indiscriminate mitosis have damaged cellular DNA, unlike cells from tissues with benign lesions. The p53 tumor suppressor gene is involved in DNA repair, explaining its overexpression in the cells that require its activity. A dependency relationship was found between p21 protein and p16, p53 and Ki67. p21 and p53 relation were clear since p53 has the ability to activate p21. p21 and Ki67 relation might be explained taking into account that the objective of p21 is to stop

the uncontrolled proliferation of cells, stopping them in the G1 phase; therefore, an increase in the cell proliferation index will lead to the overexpression of p21. The relationship between p21 and p16, both responsible for stopping the cell in the G1 phase, shows that the presence of HPV in a state of replication sets in motion cellular mechanisms that inhibit tumors.

With these results, we can confirm that the HPV infection of the oral cavity tissue has set in motion cellular mechanisms for tumor inhibitors, so this infection has a direct rela-

tionship with cancer of the oral cavity and oropharynx [17]. The literature reviewed shows a causal relationship between HPV and carcinoma of the oral cavity and oropharynx, stating that 30% of squamous tumors are caused by this virus [18]. Some studies [7], claim that the increased incidence of this type of cancer is mainly due to HPV infection, while others (9), have raised the possibility of including prevention plans. It should also be noted that some studies have shown a low oncogenic prevalence of HPV in the oral cavity [19]. Since the causal relationship between HPV and oral cancer has been demonstrated, we suggest that simple screening performed by swabbing the oral cavity would help with early treatment and surveillance to prevent the development of oral cancer. The inclusion of serotypes with the greater oral tendency in established vaccination campaigns could reduce the incidence of this cancer.

Since men are often carriers of the virus and the main transmitter to women, their inclusion in the current vaccination campaign would reduce the number of infections and thus reduce the risk of HPV-associated cancer. It would be interesting to investigate the probability of developing cancer in the oral cavity if there is an infection in this location, in order to analyze whether the costs incurred by screening and vaccination against specific oral serotypes would be useful, or whether a low probability would be a waste of public money. To conclude, the results of this study provide very interesting information and highlight possible advantages and disadvantages of HPV vaccination, since the possibility of reducing the incidence and consequent morbidity and mortality of cancer that is increasing its incidence is an excellent incentive.

References

1. Candotto V, Lauritano D, Nardone M, Baggi L, Arcuri C, Gatto R, et al. (2017) HPV infection in the oral cavity: epidemiology, clinical manifestations, and relationship with oral cancer. *J Oral Implantol* 10: 209-220.
2. Marur S, Forastiere AA (2016) Head and neck squamous cell carcinoma: update on epidemiology, diagnosis, and treatment. *Mayo Clin Proc* 91: 386-96.
3. Torre LA, Siegel RL, Ward EM, Jemal A (2016) Global cancer incidence and mortality rates and trends-an update. *Cancer Epidemiol Biomarkers Prev* 25: 1627.
4. Bruni L, Barrionuevo-Rosas L, Albero G, Serrano B, Mena M, Gómez D, et al. (2017) Human Papillomavirus and Related Diseases in the World. Summary of Report. ICO/IARC Information Centre on HPV and Cancer (HPV Information Center).
5. (2017) World Health Organization [Internet]. Human papilloma-virus.
6. Husain N, Neyaz A (2017) Human papillomavirus-associated head and neck squamous cell carcinoma: controversies and new concepts. *J Oral Biol Crani-ofac Res* 7: 198-205.
7. Tovar Martín MI, Martínez Carrillo MJ, Guerrero Tejada R (2012) Human papillomavirus detection in head and neck squamous cell carcinomas and it's clinical implications. In: Poblet Martínez E, editor. *Histopathology - reviews and recent advances: InTech*.
8. Azúa Romeo J (2005) The role of p16 modulator in human papillomavirus infection. *Rev Clin Esp*. 205: 248-251.
9. Sanabria Negrín JG (2009) Human Papillomavirus / Human Papillomavirus (HPV). *Pinar del Río Journal of Medical Sciences* 13: 168-187.
10. Giarré M, Caldeira S, Malanchi I, Ciccolini F, Leao MJ, Tommasino M (2001) Induction of pRb degradation by the human papillomavirus type 16 E7 protein is essential to efficiently overcome p16 ink4a-imposed G1 cell cycle arrest. *J Virol* 75: 4705-4712.
11. Sano T, Oyama T, Kashiwabara K, Fukuda T, Nakajima T (1998) Expression status of p16 protein is associated with human papillomavirus oncogenic potential in cervical and genital lesions. *Am J Pathol* 53: 1741-1748.
12. Belobrov S, Cornall AM, Young RJ, Koo K, Angel C, Wiesenfeld D, et al. (2018) The role of human papillomavirus in p16-positive oral cancers. *J Oral Pathol Med* 47:18-24.
13. Lim S, Lee MJ, Cho I, Hong R, Lim SC (2016) Efficacy of p16 and Ki-67 immunostaining in the detection of squamous intraepithelial lesions in a high-risk HPV group. *Oncol Lett* 11:1447-452.
14. Keating JT, Cviko A, Riethdorf S, Riethdorf L, Quade B, Sun D, Duensing S, Sheets E, Munger K, Crum C (2001) Ki 67, cyclin E and p16 ink4a are complimentary surrogate biomarkers for human papilloma virus-related cervical neoplasia. *Am J SurgPatho* 25: 884-891.

15. Contreras W, Venegas B (2015) Virus papiloma humano en cáncer oral y orofaríngeo. Revisión de la Literatura. Int J Odontostomat 9: 427-435.
16. Abbas T, Dutta A (2009) P21 in cancer: intricate networks and multiple activities. Nat Rev Cancer 9: 400-414.
17. Taberna M, Mena M, Pavón MA, Alemany L, et al. (2017) Human papillomavirus-related oropharyngeal cancer. Ann Oncol 28: 2386-2398.
18. González Díaz M, Motta Vargas LA, Moreno Torres A, Chala Galindo AI, TupazErira HA, García Robayo DA (2014) Human papillomavirus infection affects the prognosis of squamous oropharyngeal cancer. Literature Review. Univ Odontol 33: 55-63.
19. D'Souza G, McNeel TS, Fakhry C (2017) Understanding personal risk of oropharyngeal cancer: risk groups for oncogenic oral HPV infection and oropharyngeal cancer. Ann Oncol 28: 3065-3069.

Submit your manuscript to a JScholar journal and benefit from:

- ¶ Convenient online submission
- ¶ Rigorous peer review
- ¶ Immediate publication on acceptance
- ¶ Open access: articles freely available online
- ¶ High visibility within the field
- ¶ Better discount for your subsequent articles

Submit your manuscript at
<http://www.jscholaronline.org/submit-manuscript.php>