

Unilateral Panopthalmitis In Dengue Fever A Rare and Preventable Complication

Mayuri Yeole^{1*}, Himaal Dev²

¹Consultant Pediatrician, Apollo Hospitals, Sheshadripuram, Bangalore, Karnataka, India

²Consultant Intensivist, Apollo Hospitals, Sheshadripuram, Bangalore, Karnataka, India

*Corresponding author: Mayuri Yeole, Consultant Pediatrician, Apollo Hospitals, Sheshadripuram, Bangalore, Karnataka, India; E-mail: dr.yeolemayuri@gmail.com

Received Date: May 05, 2020 Accepted Date: May 17, 2020 Published Date: May 20, 2020

Citation: Mayuri Yeole (2020) Unilateral Panopthalmitis In Dengue Fever A Rare and Preventable Complication. J Ophthalmol Open Access 1: 1-4.

Abstract

Objectives: ADengue, one of the most common mosquito borne flavivirus diseases affecting humans, is spread by the Aedes aegypti mosquito. Most people infected with dengue virus are asymptomatic, while in a small proportion it is life-threatening such as Dengue hemorrhagic fever and Dengue shock syndrome. Severe dengue is defined as that associated with severe bleeding, severe organ dysfunction, or severe plasma leakage. One of the complications in Dengue disease that is being observed more frequently in recent times is the ophthalmic manifestations. Ophthalmic manifestations can involve both the anterior and posterior segment. However, only a few isolated case reports have been published. Here we report an isolated case of dengue Panopthalmitis, leading to rapidly progressive painful visual loss.

Keywords: Dengue, flavivirus, Aedes aegypti, Panopthalmitis, Severe Dengue

Abbreviations: cfDNA, cell-free DNA; EGFR, epidermal growth factor receptor; NSCLC, non-small cell lung cancer; OS, overall survival; PD, disease progression; PFS, progression-free survival; TKI, tyrosine kinase inhibitor

Introduction

Dengue fever is the most prevalent form of flavivirus infection in humans. The highest incidence occurs in Southeast Asia, India and the American tropics [1,2]. Worldwide cases of illness exceed 100 million per year [2]. Dengue fever is a mosquito-borne disease that is commonly found in the tropics. Dengue virus belongs to the Flavivirus genus of the family Flaviviridae and its members include the four antigenically-related serotypes of dengue virus (DENV 1-4). It is transmitted to humans by the bite of an infected female Aedes mosquito, usually the Aedes aegypti mosquito. Dengue hemorrhagic fever (DHF) is a severe and potentially fatal form of the disease. Twenty five thousand deaths are reported annually to the World Health Organization (WHO).

Ophthalmic complications associated with DF and DHF have not been classically described. This complication is being observed more frequently in recent times. However, only a few isolated case reports have been published. Dengue related ocular complications range from 10% to 40% [3,4]. The ocular manifestations range from sub-conjunctival hemorrhage to posterior segment manifestations [5]. The ocular manifestations reported to be associated with dengue infections are mostly posterior segment manifestations like macular edema, vascular occlusions, chorioretinitis, vasculitis with retinal bleeding or cotton wool spots [6,7]. Anterior segment commonly manifests with subconjunctival hemorrhage due to thrombocytopenia [8]. Here we report an unusual manifestation of dengue fever presenting unilaterally with extensive Panophthalmitis.

Case report

A 14 year old boy presented to us with history of high grade fever since 1 week, associated vomiting since 3-4 days. He had presented with Dengue shock syndrome at other hospital as per history provided, with Dengue NS1 being positive, Platelet count being 33,000/cumm. He was treated for shock as per protocol and transfused with random donor platelets. On day 2 of admission child complained of retro orbital pain, periorbital swelling over the right eye. Patient was brought to us with blood and serous discharge from right eye for further intervention. All hematological investigations were within normal limit, platelet count being 67,000/cumm and Dengue IgM being positive. During the course of treatment we sent culture swab from affected eye, which were negative for any organism. MRI Brain with Orbit was suggestive of right eye proptosis with features of Panophthalmitis, orbital cellulitis and abscess of right eye. On bedside examination, there was no perception to light noted in right eye; whereas the left eye was normal. We started the child on broad spectrum intravenous and topical antibiotics, also systemic steroids on day 2 of admission and saw a significant improvement in restoration of eye movements in right eye except for abduction. He also received periocular antibiotics. Proptosis had eventually reduced with no perception to light, corneal infiltrates present, and fundus was still not visible. He recovered from systemic dengue illness with platelet count at the time of discharge being 1.8 lakh/cumm but still had no perception of light in right eye and was advised for the evisceration, however due to financial constraints patient failed to follow up (figure 1).

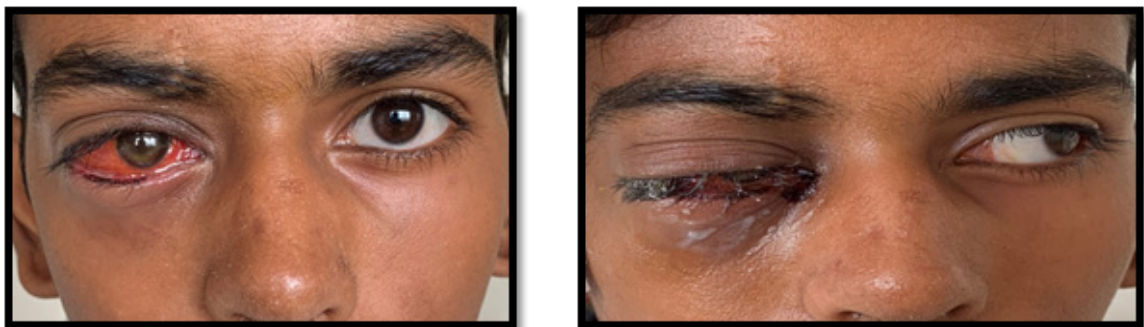


Figure 1: Pre and post systemic steroid response

Discussion

Dengue is one of the most important emerging viral diseases of humans in India, afflicting humanity in terms of morbidity and mortality [9]. The ocular manifestations of dengue have been reported in all age groups, but more commonly in early thirties [3,6]. Vision threatening complications of dengue have been reported at the end of 1st week of dengue fever as this is the phase coinciding with nadir of thrombocytopenia [6]. Panophthalmitis is a rare complication, which has been reported in only 2 cases in literature till date [10,11].

Panophthalmitis is a severe involvement of the anterior and the posterior segments of the eye, presenting with marked lid edema, proptosis, limitation of ocular movements and high IOP. The common symptoms include ocular pain, blurring of vision, and ocular discharge. During the later stages of infection, the patients may develop severe inflammation with chemosis, proptosis, and hypopyon that can lead to blindness [12]. Though the pathogenesis of these changes is not yet known, their clinical presentation and behavior are indicative of an immunogenic etiology rather than infective [13]. The course of the ocular complications, such as systemic DF, is generally self-limiting. However, immediate high dose steroids at presentation, followed by a rapid taper, has been suggested and tried with varying success to suppress and minimize the inflammatory damage [14].

Proptosis in dengue fever could be due to retro bulbar hemorrhage or panophthalmitis [10]. Possible mechanism for globe rupture could be an increase in intraocular and intraorbital pressure secondary to retro bulbar, suprachoroidal, and intravitreal hemorrhages [15,16]. Exact etiology of Panophthalmitis is not known. It may be due to the viremia causing embolization of infective material through retinal vessels, occurring at the nadir in platelet count. After establishing a septic focus in the retina, infection could have disseminated throughout the retina, vitreous, and anterior segment [11].

Panophthalmitis, though rare in dengue, is vision-threatening. Hence, a systematic ophthalmic examination and intervention in dengue patients with ocular symptoms is mandatory. Physicians should be aware and vigilant toward patients with dengue related ophthalmic complaints, as the patients may develop life threatening Panophthalmitis.

Conclusion

The onset of visual symptoms usually occurs at the lowest platelet level, blurring of vision typically coincides with the nadir of thrombocytopenia and occurs close to one week after onset of fever. Hence a very careful observation by fundus examination may be required during this period. The clinical features of dengue retinopathy includes any one or all of the following such as retinal edema, blot hemorrhages, cotton wool spots, anterior uveitis, exudative retinal detachment [12]. Even though the disease is self-limiting and has a good prognosis it can also result in Panophthalmitis and vision loss. Topical, periocular, oral, intravenous antibiotics, steroids and immunoglobulins have been advocated for the management of dengue associated uveitis and optic neuritis. The inference is that the clinicians should have heightened awareness of dengue related ophthalmic complications and should facilitate prompt referral for ophthalmic assessment and management, with early administration of steroids systemic or intravitreal might help in halting the ocular damage.

References

1. Halstead SB (1966) Mosquito-borne hemorrhagic fevers of South and South-east Asia. *Bull World Health Organ.* 35:3.
2. Halstead SB (1990) Global epidemiology of dengue hemorrhagic fever. *Southeast Asian J Trop Med Public Health.* 21:636
3. Kapoor HK, Bhai S, John M, Xavier J (2006) Ocular manifestations of dengue fever in an East Indian epidemic. *Can J Ophthalmol.* 41:741-46
4. Su DH, Bacsal K, Chee SP, Flores JV, Lim WK, Cheng BC et al. (2007) Dengue Maculopathy Study Group. Prevalence of dengue maculopathy in patients hospitalized for dengue fever. *Ophthalmology* 114:1743-47
5. Ranjan S, Ranjan R (2013) Dengue-related Ocular Pathology: A review. *International Journal of Biomedical Research* 4:451-60
6. Chan DP, Teoh SC, Tan CS, Nah GK, Rajgopalan R, Prabhakar Gupta MK et al. (2006) The Eye Institute Dengue-Related Ophthalmic Complications Workgroup: Ophthalmic complications of dengue. *Emerg Infect Dis* 12: 285-89
7. Lim WK, Mathur R, Koh A, Yeoh R, Chee SP (2004) Ocular manifestations of dengue fever. *Ophthalmology.* 111: 2057-64
8. Wen KH, Sheu MM, Chung CB, Wang HZ, Chen CW (1989) The ocular fundus findings in dengue fever. *The Kaohsiung Journal of Medical Sciences* 5:24-30.
9. Saranappa SB, Sowbhagya HN (2012) Panophthalmitis in dengue fever. *Indian Pediatr* 49:760.
10. Sriram S, Kavalakatt JA, Pereira AD, Murty S (2015) Bilateral panophthalmitis in dengue fever. *Ann Trop Med Public Health* 8:217-8.
11. Okada AA, Johnson RP, Liles WC, D'Amico DJ, Baker AS (1994) Endogenous bacterial endophthalmitis. Report of a 10-year retrospective study. *Ophthalmology* 101:832-8.
12. Teoh SC, Chan DP, Nah GK, Rajagopalan R, Laude A, Ang BS, et al. (2006) A Re-look at Ocular Complications in Dengue Fever and DHF. *Dengue Bull.* 30
13. Teoh SC, Chan DP, Augustinus L, Chee CK, Lim TH, Goh KY (2006) The Eye Institute Dengue Related Ophthalmic Complications Workgroup. Dengue chorioretinitis and dengue-related ophthalmic complications. *Emerg Infect Dis* 12:285-9
14. Nagaraj KB, Jayadev C, Yajmaan S, Prakash S (2014) An unusual ocular emergency in severe dengue. *Middle East Afr J Ophthalmol* 21:347-9.
15. Kulkarni AG, Athale N, Sheth K, Rathi A, Shinde V, Deshmukh S, et al. (2016) Globe rupture – A rare ocular manifestation of dengue fever in convalescent phase. *Int J Sci Res* 5:1727-9.

Submit your manuscript to a JScholar journal and benefit from:

- ¶ Convenient online submission
- ¶ Rigorous peer review
- ¶ Immediate publication on acceptance
- ¶ Open access: articles freely available online
- ¶ High visibility within the field
- ¶ Better discount for your subsequent articles

Submit your manuscript at
<http://www.jscholaronline.org/submit-manuscript.php>