

## A Case Report on Moyamoya Disease

T.V. HarshaVarun<sup>\*1</sup>, Ch.Gowthami<sup>1</sup>, G.Vanathi<sup>1</sup>, Dr. R.E. Ugandar<sup>2</sup>, Dr. C. Bhargav reddy<sup>2</sup>

<sup>1</sup>Santhiram College of Pharmacy, Nandyal, Kurnool DT, Andhra Pradesh, India

<sup>2</sup>Santhiram Medical College & General Hospital, Nandyal, Kurnool DT, Andhra Pradesh, India

\*Corresponding author: T.V Harsha Varun, JNTUA, Santhiram College of Pharmacy, E-mail: harsha21varun@gmail.com; Tel: 8500553938

Received Date: September 11, 2019 Accepted Date: November 22, 2019 Published Date: November 25, 2019

Citation: T.V. HarshaVarun (2019) A Case Report on Moyamoya Disease. J Surg Proce Case Rep 1 : 1-5.

### Abstract

Moyamoya is a rare idiopathic progressive vaso-occlusive disease characterized by an irreversible condition of blood supply through blood vessels to the brain as they enter the skull. It is a rare cause of cerebral stroke in adults. We have reported a case of a female patient aged 26 years who was admitted at our hospital with chief complaints of right-sided weakness, slurring of speech, weakness of right lower limb, weakness and numbness of left lower limb from past one month and sudden fall down on the day of admission. The patient delivered a male baby five weeks prior to the hospitalization and she was normal after delivery and the complained symptoms were observed by the patient from the second week of delivery. The MRA findings of the patient reported stenosis in the terminal internal carotid artery and posterior circulation with Moyamoya collaterals "puff of smoke". The patient was initially suggested for surgery, since she was a lactating mother to her baby she has been treated with medication such as Aspirin, Atorvastatin, Thyroxine sodium & Warfarin. The patient was discharged from the hospital after two days.

**Keywords:** Moyamoya; Puff of smoke; Stenosis; Recurrent stroke; intracranial hemorrhage.

**Abbreviations:** MMD-Moya Moya disease, MRA-Magnetic Resonance Angiogram, CSF- Cerebrospinal fluid, MRI- Magnetic resonance imaging, MCA- Middle cerebral artery, TIAs- Transient ischemic attack, ICA- Internal carotid artery, EC-IC- Extra cranial-intracranial, EDAS- Encephalo-Duro-arterio-angiogenesis, MR- Magnetic resonance, STA-Superficial temporal artery.

## Introduction

MoyaMoya is a chronic progressive occlusion of the circle of Willis arteries. It leads to the development of characteristic collateral vessels which can be observed on imaging, particularly through Cerebral angiography. The term MoyaMoya refers to an appearance on the angiograph of abnormal vascular collateral networks that develop adjacent to the stenosis vessels. The steno-occlusive areas are bilateral, but unilateral involvement does not exclude the diagnosis. The disease may develop in children and adults [1].

MMD is now seen throughout the world with bimodal age of onset, with children presenting around age 5 and adults around age 40 [2]. The presentation in a child is typically a stroke or a transient ischemic attack, in adults it is typically a hemorrhage. Less commonly, MMD may present with a headache or a seizure. MMD affects bilateral internal carotid arteries, whereas a unilateral presentation of the same underlying pathology is known as Moyamoya syndrome and associated with conditions like Down syndrome, neurofibromatosis type 1 and sickle cell disease.

## Case Description

A 26years female patient was admitted in neurology department IP NO-1920007764 with chief complaints right-sided weakness for 1month, weakness of right upper limb, weakness, and numbness of right upper limb, sudden fall down, occasional blinking of the right eye, unable to handle the baby, slurring of speech. General physical examination showed no abnormalities. Her past medical history was hypothyroidism and using thyronorm-75mcg. Vital signs include [Blood Pressure-130/90mm Hg, Heart rate-82b/m, Temperature-97°C, and Respiratory rate-18c/min].

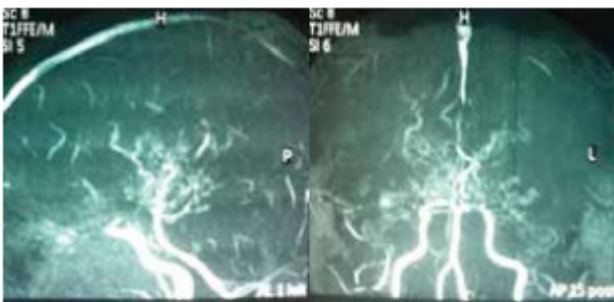


Figure 1: MRA shows stenosis in the terminal ICA and posterior circulation with Moyamoya collaterals “puff of smoke”.

On neurological examination the tone was decreased left side, hematological and CSF was normal, MRI suggestive of right-sided hemiplegic with frontal gliotic changes and sub-acute right occipital MCA zone infarct. MR angiography brain revealed Moyamoya collaterals in both the basal ganglia region, which gives a “puff of smoke” appearance.

## Etiology

The cause of Moyamoya disease is Unknown. The disease is believed to be genetic. People reported history in 10% of patients with this disorder. People with Moyamoya have been found to have a higher incidence of elevated thyroid antibodies. The evidence suggests that the RNF213 gene on chromosome 17q25.3 is an important susceptibility factor for MMD in East Asian populations. However, it suggests abnormalities may play some role in Moyamoya disease [3].

## Treatment

Surgical revascularization is the primary treatment of MMD. Before studies have estimated that without treatment, around two-thirds of Moya Moya patients have the progression of symptoms over five years, with poor outcome sources [15]. However, after surgical treatment, the symptomatic progression is reduced only 2.6%, with almost all the patients remaining stroke-free at a time point of five years after surgery [16, 17]. The present patient discussed above was treated successfully with a direct extra cranial-intracranial (EC-IC) arterial bypass surgery. The surgical revascularization options can split into direct, indirect, and combined approaches. The direct EC-IC bypass performed commonly used in adult patients. The indirect encephalon-Duro-arterial-syngiosis (EDAS) procedure involves laying down a branch of superficial temporal artery onto the brain surface, allowing for neovascularization supplying blood flow to the tissue indirectly rather than a direct anastomosis.

Medical treatments have been proposed include, including antiplatelet agents, antifibrinolytic agents, vasodilators and fibrinolytic agents, the efficacy of medical treatments has been proved in clinical trials. Epilepsy cases have managed using anticonvulsants. Ischemic episodes and thrombosis can be managed using antiplatelet, then possibly preventing the progression of MMD as well [18].

Surgical treatments are divided into three groups: Direct, indirect and combined. Direct bypass includes vein grafts and extra cranial-intracranial anastomosis of the STA to the MCA (STA-MCA anastomosis). An extra cranial-intracranial bypass was first performed in 1972 by Yaşargil. The indirect

bypass can involve any several procedures including encephaloduroarteriosynangiosis, encephalomyoarteriosynangiosis, encephaloarteriosynangiosis, encephalomyosynangiosis, durapexy, multiple cranial bur holes, and transplantation of omentum. The indirect procedures bring in circulation to intracranial regions by newly developed vasculature from sutured tissue. Indirect surgeries are better for patients without good cortical branches for anastomosis. These procedures may not be enough to prevent further ischemia [19-21].

Brand Name	Generic Name	Dose	Route	Frequency
T.Ecosprin	Aspirin	325mg	Oral	OD
T.Tonact	Atorvastatin	80mg	Oral	OD
T.Thyronorm	Thyroxine sodium	75mcg	Oral	OD
T.Warfarin	Warfarin	4mg	Oral	OD

### Presentation and Natural history

MMD cases are typically present acutely with various cerebrovascular events including intracranial hemorrhage, TIAs, brain infarction, and epileptic seizures. The Ministry of Health and Welfare of Japan has defined 4 types of MMD with the following presentation percentages: Ischemic 63.4%, hemorrhagic 21.6%, epileptic 7.6%, and "other" 7.5% [4]. There are also asymptomatic cases in which MMD is found incidentally on angiography [5]. They stated before, ischemic type of MMD predominates in childhood, making up 69% of cases in patients under 10 years old. Some cases involve  $\geq 1$  one symptom, including 40% of patients with TIAs and 29% with infarction resulting in motor paresis and disturbances of sensation, consciousness, speech [4-6]. Ischemic symptoms are often instigated by hyperventilation. The symptoms are present repetitively and can result in motor aphasia, cortical blindness, even a vegetative state. The course of the disease often leads to mental retardation and low IQ over the long term [7].

Further investigation into the progression of unilateral to bilateral MMD has shown that neither unilateral cases nor their progression to bilateral cases are rare. Three separate studies reviewed a total of 512 patients with MMD, 14% of whom had unilateral disease at diagnosis. 32 (44%) of the original 72 unilateral cases progressed to bilateral cases. The 4 studies all showed an average time of progression between 1.5 and 2.2 years [8,9]. The researchers suggest that predictors of progression as follows: Abnormalities on the initial angiogram of the contralateral ACA, internal carotid artery (ICA) or MCA, previous history of cardi-

ac anomalies, cranial irradiation, Asian heritage. Younger age of onset (younger than 7 years old) corresponded to faster progression in a study by Smith and Scott [9]. The only factor noted to predict no progression was a normal angiogram of the contralateral side at diagnosis.

### Discussion

Moyamoya disease is a rare disease characterized by multiple occlusions of the cerebral circulation with an unusual net-like system of collaterals. In Japanese, Moyamoya means "hazy". The disease derives its peculiar name from the angiographic appearance of cerebral vessels in the disease that resembles a "puff of smoke". A most common presentation is recurrent episodes of cerebral ischemia manifesting clinically as focal deficits, paresthesia, and seizures [10]. Previously thought that prevalent only in Japan, cases have now been reported from across the world [11, 12]. However, the majority of the cases are reported in Asia and other non-Caucasian regions [13].

The tiny vessels are the Moyamoya vessels for which the disease was named. Inadequate blood supply that leads to reduced oxygen supply to the brain and the oxygen deprivation that causes the signs of Moyamoya. The process of narrowing of cerebral vessels seems to be a reaction of brain blood vessels to a wide variety of external stimuli or genetic defects. Such Conditions are neurofibromatosis-1, Down's syndrome, congenital heart defects, antiphospholipid syndrome, and thyroiditis be associated with Moyamoya disease in the literature [14].

The incidence of MMD is highest in Japan but has now reported in ethnicities across the world, such as the Hispanic male we present here. Interestingly, the disease is twice as common in females compared to males. MMD has a bimodal age of presentation. Children around 5 years of age present with symptoms of brain ischemia, often triggered by hyperventilation. Adults present in their mid-40s with recurrent headache and intracranial hemorrhage, often in the subcortical brain structures such as the basal ganglia. The hemorrhage is likely due to rupture of fragile collateral vessels or the development of cerebral aneurysms from shear stress, headaches may be due to dilated leptomeningeal collateral vessels stimulating nociceptors in the Dura.

## Conclusion

In conclusion, the diagnosis of Moyamoya disease is now accessible to modern brain imaging techniques (MRI and MRA). It is important to be familiar with the clinical manifestations and MRI/MRA findings in Moyamoya disease to make an early diagnosis. A better understanding of the natural history of patients with Moyamoya disease as well as the benefit of the various treatment modalities is needed.

Surgery can be beneficial, particularly if the diagnosis of Moyamoya disease is made early. However, further prospective studies are necessary. Optimization of surgical techniques, perioperative care and anesthesia likely to improve the benefit of surgical revascularization for future patients. The long-term neurologic and radiologic follow-up is essential in adult patients with Moyamoya disease to prevent additional stroke events and improve outcomes.

## References

1. Paul H Tanda Do, Jonathan G Below (2009) The journal of American osteopathic association. 109: 547-553.
2. Scott RM, Smith ER (2009) Moyamoya disease and Moyamoya syndrome. *N Engl J Med* 360: 1226-1237.
3. Kim SJ, Heo KG, Shin HY, et al. (2010) Association of thyroid autoantibodies with Moyamoya-type cerebrovascular disease: a prospective study. *Stroke* 41: 173-176.
4. Fukui M (1997) Current state of study on Moyamoya disease in Japan. *Surg Neurol* 47: 138-143.
5. Kuroda S, Hashimoto N, Yoshimoto T, Iwasaki Y (2007) Radiological findings, clinical course, and outcome in asymptomatic moyamoya disease: Results of a multicenter survey in Japan. *Stroke* 38: 1430-1435.
6. Wilmoth J, Skytthe A, Friou D, Jeune B (1996) The oldest man ever? A case study of exceptional longevity. *Gerontologist* 36: 783-788.
7. Ishii K, Isono M, Kobayashi H, Kamida T (2003) Temporal profile of angiographical stages of Moyamoya disease: When does Moyamoya disease progress? *Neurol Res* 25: 405-410.
8. Kelly ME, Bell-Stephens TE, Marks MP (2006) Progression of unilateral Moyamoya disease: Aclinical series. *Cerebrovasc Dis* 22: 109-115.
9. Smith ER, Scott RM (2008) Progression of disease in unilateral Moyamoya syndrome. *Neurosurg Focus* 24: E17.
10. O Vernet, JL Montes, AM O'Gorman S, et al. (1996) "Encephaloduroarterio-synangiosis in a child with sickle cell anemia and Moyamoya disease," *Pediatric Neurology* 226-230.
11. NM Wetjen, PC Garell, NV Stence, and CM Loftus (1997) "Moyamoya disease in the midwestern United States," *Clinical Neurology and Neurosurgery*, supplement 2 S31-S35.
12. N Khan, B Schuknecht, E Boltshauser et al, (2003) "Moyamoya disease and Moyamoya syndrome: experience in Europe; choice of revascularization procedures," *Acta Neurochirurgica* 1061-1071.

13. Y Natori, K Ikezaki, T Matsushima and M Fukui (1997) "Angiographic Moyamoya" its definition, classification, and therapy," *Clinical Neurology and Neurosurgery* S168–S172.
14. J Lutterman, M Scott, R Nass, and T Geva (1998) "Moyamoya syndrome associated with congenital heart disease," *Pediatrics* 101: 57–60 .
15. Scott RM, Smith ER (2009) Moyamoya disease and Moyamoya syndrome. *N Engl J Med.* 360: 1226-1237.
16. Fung LW, Thompson D, Ganesan V (2005) Revascularisation surgery for pediatric moyamoya: a review of the literature. *Childs Nerv Syst.* 21: 358-364.
17. Choi JU, Seok Kim D, Kim EY, Lee KC (2002) Natural history of Moyamoya disease: comparison of the activity of daily living in surgery and no surgery groups. *Clin Neurol Neurosurg* 99: S11-S18.
18. Kuroda S, Hashimoto N, Yoshimoto T, Iwasaki Y (2007) Radiological findings, clinical course, and outcome in asymptomatic Moyamoya disease: Results of a multicenter survey in Japan. *Stroke* 38: 1430-1435.
19. Fukui M, Kono S, Sueishi K, Ikezaki K (2000) Moyamoya disease. *Neuropathology* 20Suppl: S61-4.
20. Kawaguchi S, Okuno S, Sakaki T (2000) Effect of the direct arterial bypass on the prevention of future stroke in patients with the hemorrhagic variety of Moyamoya disease. *J Neurosurg* 93: 397-401.
21. Masuda J, Ogata J, Yamaguchi T, Mohr J, et al (2004) Pathophysiology, Diagnosis, and Management. 4th ed. New York: Churchill Livingstone 603-618.

**Submit your manuscript to a JScholar journal and benefit from:**

- ¶ Convenient online submission
- ¶ Rigorous peer review
- ¶ Immediate publication on acceptance
- ¶ Open access: articles freely available online
- ¶ High visibility within the field
- ¶ Better discount for your subsequent articles

Submit your manuscript at  
<http://www.jscholaronline.org/submit-manuscript.php>