

## A Large Saccular Pseudo Aneurysm of Ascending Aorta- A Rare Post-Operative Complication of Aortic Annulus Enlargement

Akshatha H\*, Anup Charles Steven, Sanjay K Cherian and KM Cherian

Department of Cardiothoracic and vascular surgery, Frontier lifeline hospital, Chennai, Tamil Nadu, India

\*Corresponding author: Akshatha H, Department of Cardiothoracic and vascular surgery, Frontier lifeline hospital, Chennai, Tamil Nadu, India, Tel: +91 9611129695, E-mail: hakshatha18@yahoo.in

Received Date: July 03, 2021 Accepted Date: August 03, 2021 Published Date: August 05, 2021

Citation: Akshatha H (2021) A Large Saccular Pseudo Aneurysm of Ascending Aorta- A Rare Post-Operative Complication of Aortic Annulus Enlargement. J Surg Proce Case Rep 3:1-4.

### Abstract

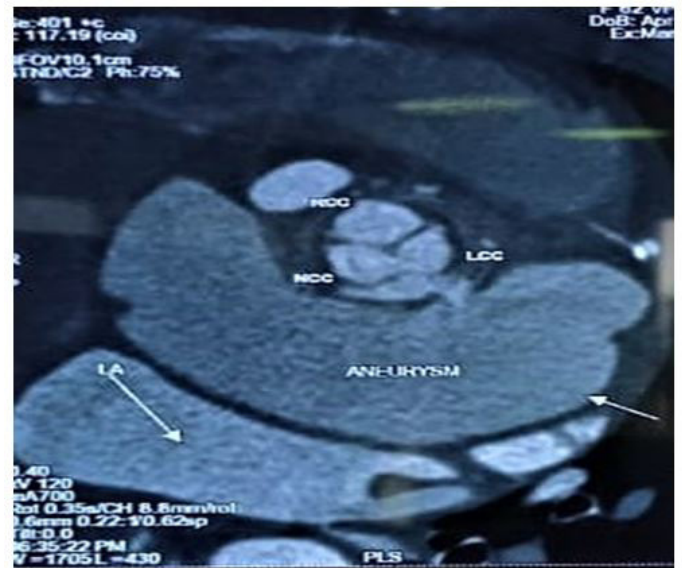Aortic annulus enlargement is done during valve replacement in patients with a small annulus relative to the body surface area. There are multiple techniques which have good results. The rare complications associated with these procedures include paravalvular leakage, anastomotic dehiscence, graft aneurysm, aortic dissection, mitral valve insufficiency and endocarditis. Here, we present a case of pseudo aneurysm of ascending aorta that developed post aortic valve replacement and Nick's technique of aortic annulus enlargement.

**Keywords:** Aortic Annulus Enlargement; Pseudo Aneurysm; Nick's Technique

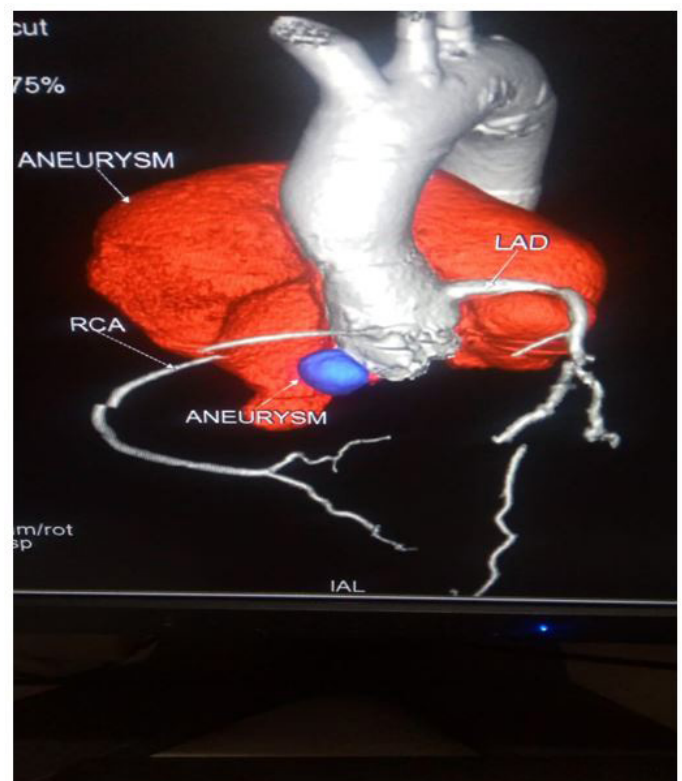## Case report

A 61-year-old female presented to our institution with complaints of chest pain and difficulty in breathing. She had a past history of aortic valve replacement (21mm LABCOR bio-prosthetic valve) with aortic root enlargement by Nicks technique for severe calcific aortic stenosis 17 months ago (18.10.2019). Patient's native aortic valve was tricuspid and ascending aorta diameter was 25mm at the time of operation. Since aortic annulus was admitting only No.19 Hegar's dilator, aortic annulus was enlarged by Nick's technique with PTFE patch reconstruction using 5-0 prolene.

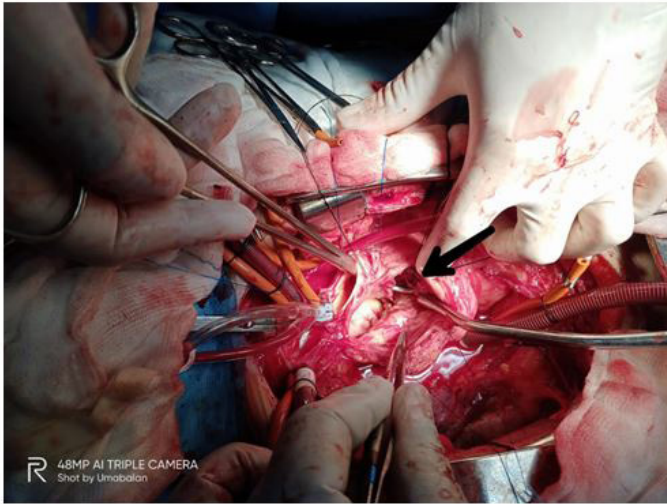
On evaluation, Transthoracic echocardiography showed functional aortic prosthetic valve with grade II paravalvular leak with aneurysmal dilatation of aortic root. CT Angiography of coronaries and aortic root showed a well-defined saccular aneurysmal outpouching arising from non-coronary sinus and encircling major portion of aortic root and proximal ascending aorta. It had a transverse diameter of 98.5mm. A thrombus was noted in the right anterior aspect of the aneurysm. The sac was compressing left atrium, infra-azygous SVC/right atrium, superior pulmonary veins and right coronary ostium. The mid and distal right coronary was normal. There was also narrowing of proximal LAD due to mass effect by the aneurysm. Another small irregular saccular aneurysmal outpouching of 13.4x10.3mm was seen arising from right coronary sinus, 6mm below the right coronary artery origin. Patient underwent redo surgery through sternum. Cardiopulmonary bypass was established with high aortic and bicaval cannulation. Horizontal aortotomy done after root cardioplegia. The bioprosthetic valve was in situ. A large 1cm rent was noted in the paravalvular area between non coronary and left coronary cusp. The rent was closed using PTFE patch with 5-0 prolene. On releasing the aortic cross clamp, bleeding was noted posteriorly. Aorta was again cross clamped and transected. Pulmonary artery was also transected to localise the bleeding point. A second rent measuring 1cm was noted between right and left coronary cusps. PTFE patch reconstruction done using 5-0 prolene. Pulmonary artery repaired with 6-0 prolene continuous sutures. Aortic continuity restored using 22mm interposition graft to avoid tension at the suture line. Patient weaned off bypass uneventfully. Chest closed in usual fashion. Postoperative period was uneventful and patient discharged in stable condition (Figures 1,2,3 & 4).



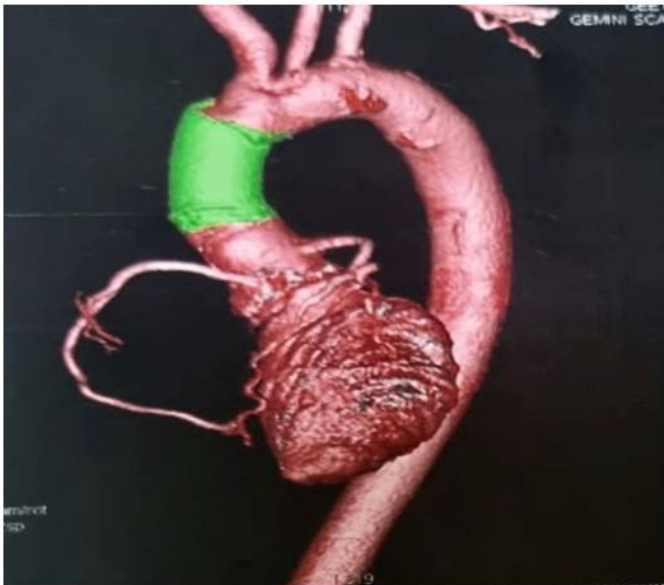**Figure 1:** CT angiography image- a large aneurysm arising from the non-coronary cusp and compressing the left atrium(LA)



**Figure 2:** 3D reconstruction image- the aneurysm is seen compressing the right coronary artery(RCA) and left anterior descending artery(LAD)



**Figure 3:** Intraoperative image- The tip of the black arrow points towards the rent in the ascending aortic wall which caused the pseudo-aneurysm



**Figure 4:** postoperative CT aortogram showing the vascular stent (green) in ascending aorta

## Discussion

In a patient with small aortic annulus, patient-prosthesis mismatch can occur on replacing with a valve that is smaller with respect to the body surface area. This can be prevented by supplementing AVR with different techniques of aortic root enlargement like Nick's, Manouagian and Konno-Rastan. Annulus reconstruction can be done using various natural (autologous or bovine glutaraldehyde fixed pericardium) and synthetic (Dacron, Teflon and polytetrafluoroethylene) grafts. But these techniques are associated with long term complications like paravalvular leakage, anastomotic dehiscence, graft aneurysm, aortic dissection, mitral valve insufficiency and endocarditis [1-3].

Pseudo aneurysm is a pulsating haematoma that develops secondary to anastomotic dehiscence. The presence of friable peri annular tissue contributes to anastomoses failure. Surgical management is always indicated as it can lead to potentially lethal complications [4].

Here, we present a case of a large saccular pseudo aneurysm of ascending aorta with compression over coronary circulation that developed just 17 months after the initial operation. Intraoperatively, it was noted that the initial PTFE patch had given away resulting in pseudo aneurysm.

Ascending aortic pseudo aneurysms may be asymptomatic or can cause symptoms due to compression on adjacent vascular structure, chambers, aortic graft and may obstruct blood flow. Other potential complications include thromboembolism, rupture, erosion into pulmonary artery and fistula formation.

Late post-operative aneurysms have been reported following aortic root enlargement with pericardial patch, although the incidence is very low [5-7]. There is not much literature on development of this complication following annuoplasty with synthetic material like PTFE patch. Furthermore, there is insufficient data to state which material is ideal for enlargement of aortic annulus.

In our patient, we presume a anatomic high pressure area, inadequate length of patch or sub clinical endocarditis may have resulted in anastomotic dehiscence with subsequent aneurysm formation.

## Conclusion

Pseudo aneurysm of ascending aorta post enlargement of aortic annulus is a rare but reported complication, the diagnosis of which itself is an indication for surgery. Further studies are needed to identify the cause, standardise technique and improve on prosthesis selection. New techniques like replacement of aortic valve with a homograft and Ozaki procedure need to be tested in cases with small aortic annulus. It is also necessary for these patients to be on long term follow up for early diagnosis and prompt surgical treatment to avoid catastrophic consequences.

## References

1. Alexander Kulik (2010) Aortic root enlargement: worth the effort? *Annals of thoracic surgery* 90: 703-5.
2. Jayesh Dhareshwar, Thoralf M, Sundt III, Joseph A Dearani (2007) Aortic root enlargement: what are the operative risks?, *The journal of thoracic and cardiovascular surgery* 134: 916-24.
3. Uberto Bortolotti, Aldo D Milano, Michele Celiento (2014) Enlargement of the aortic annulus during aortic valve replacement: a review, *The journal of heart valve disease* 23: 1.
4. Ilhan Golbasi, Cemal Kemaloglu, Ozan Erbasan, Omer Bayezid (2017) surgical repair of a pseudoaneurysm of the ascending aorta to pulmonary artery fistula after replacement of the ascending aorta and aortic valve, *Clinics in surgery-vascular surgery* 2: 1534.
5. Ana Lopez Marco, Omar Nawaytou, Ulrich O Von Oppell (2013) late aortic aneurysm after supraavalvar aortic stenosis repaired with autologous pericardial patch. *Annals of thoracic surgery* 95: 346-8
6. Hamidreza Pouraliakbar, Maryam Pourmojib, Yousef Rezaei, Saeid Hosseini, aneurysm formation of pericardial patch in Manouguian procedure, *Journal of Saudi Heart Association*, 2018;30:328-330.
7. Sang Min Park, Haemin Jeong, Kyung-Soon Hong, Christopher Kim (2016) A huge saccular aortic aneurysm compressing right coronary artery 7 years after aortic valve replacement due to bicuspid aortic valve insufficiency- a rare case report, *Medicine* 95: 40(e4860).

### Submit your manuscript to a JScholar journal and benefit from:

- ¶ Convenient online submission
- ¶ Rigorous peer review
- ¶ Immediate publication on acceptance
- ¶ Open access: articles freely available online
- ¶ High visibility within the field
- ¶ Better discount for your subsequent articles

Submit your manuscript at  
<http://www.jscholaronline.org/submit-manuscript.php>