

## Spontaneous Retroperitoneal Haematoma Following Caesarean Section. Case Report and Review of the Literature

Federico A Rovegno\*, Gustavo Lemme and Agustin R Rovegno

Division of Urology, Department of Surgery, CEMIC University Hospital, Buenos Aires, Argentina

\*Corresponding author: Federico A Rovegno, Division of Urology, Department of Surgery, CEMIC University Hospital, Buenos Aires, Argentina, Tel: 07920610165, E-mail: federicoagustin605@gmail.com

Received Date: January 26, 2022 Accepted Date: February 26, 2022 Published Date: February 28, 2022

Citation: Federico A Rovegno (2022) Spontaneous Retroperitoneal Haematoma Following Caesarean Section. Case Report and Review of the Literature. J Urol Renal Health 1: 1-4.

### Abstract

Retroperitoneal haematomas (RH) are rare clinical entities, have many causes and can be potentially life-threatening. Experience in obstetrics is available mostly from case reports and therefore its incidence is unknown. Specific causes from obstetric point of view are trauma, hysterectomy, traumatic vaginal delivery, inadequate haemostasis during caesarean section, manual removal of placenta, anticoagulation therapy. Retroperitoneal haematomas are rare clinical entities have many causes and can be potentially life-threatening with considerable variability in morbidity depending on the speed and amount of bleeding. We present a patient with a retroperitoneal hematoma that developed four days following a caesarean section.

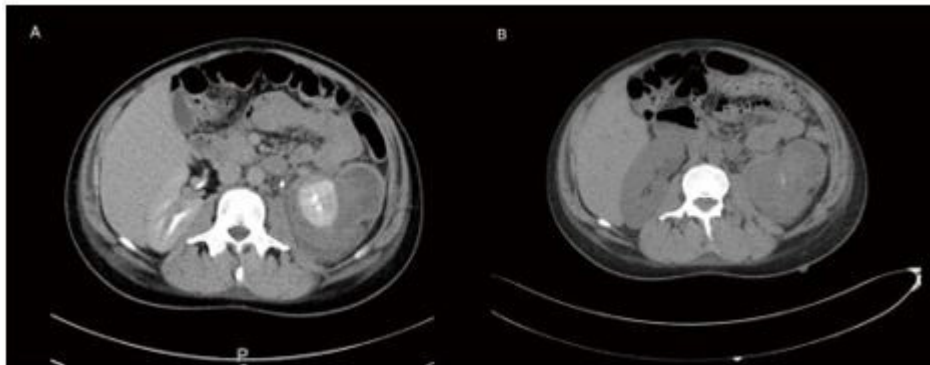
**Keywords:** Retroperitoneal Haematoma; Caesarean Section; Renal Haemorrhage

## Case Report

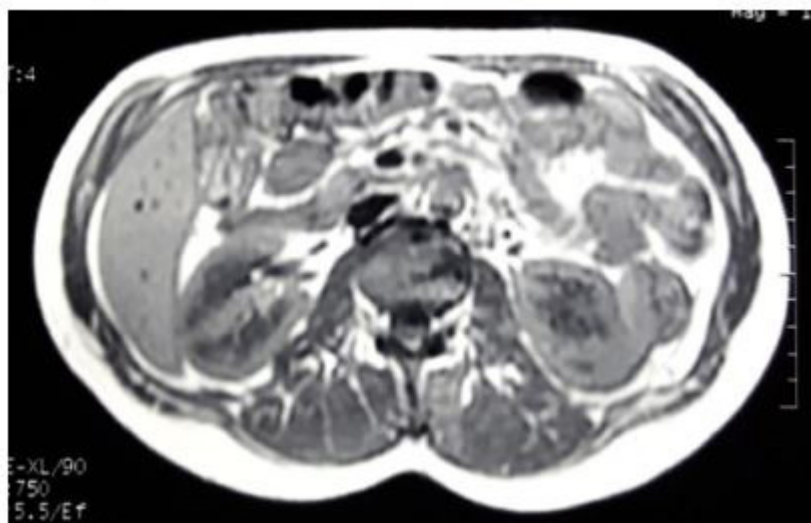
A 38-year-old woman, without any significant past medical history, was in her third pregnancy, on the 38 week of gestation. She had two previous caesarean section. The previous pregnancies were uncomplicated, and another caesarean section was carried out without any complications. The patient had an unremarkable postoperative course and was discharged home on the third postoperative day.

The following week, the patient started complaining of left sided abdominal pain not responding to analgesics, thus she was re-admitted. Her abdomen was not distended, guarding and tenderness was note on the left side.

Her general condition was good with blood pressure 110/80 mmHg, pulse 80 bpm and temperature 37.2C. Her coagulation profile, platelets and hemoglobin were within normal ranges. A Computed Tomography (CT) of the abdomen and pelvis showed a retroperitoneal hematoma measuring 8 cm x 6 cm involving the peri-renal space (Figure 1A). Angiography and transarterial embolization were discuss, but not indicated as patient remained haemodynamically stable. In the following days vital signs were within normal range, moreover there were no changes in hemoglobin levels and pain disappeared. Angiography and embolization were not required. A subsequent CT, requested to assess the kidney and the size of the hematoma, revealed a reduction in hematoma size (Figure 1B). The patient was discharged home on the tenth day of hospitalization. A Magnetic Resonance (MRI) scan was performed at 3 months that showed a greater reduction in hematoma (Figure 2).



**Figure 1:** A) Computed Tomography (CT) of the abdomen and pelvis showed a retroperitoneal hematoma measuring 8 cm x 6 cm involving the peri-renal space; B) Subsequent CT revealed a reduction in hematoma size



**Figure 2:** MRI scan at 3 months that showed a greater reduction in hematoma

## Discussion

Pregnancy is recognized as one of the predisposing conditions to develop retroperitoneal hematomas. The hormonal changes during pregnancy are known to prompt vascular wall weakening, increased cardiac output, and intravascular volume [1-4].

In the last four decades the rate of maternal mortality from these catastrophic events has decreased dramatically, from 89 to 10% reflecting advances in imaging and critical care. Similarly, the foetal survival has improved from 0 to 53% during the same period [2].

Again, the outcome depends on the aetiology, for example maternal and foetal mortality can be as high as 75 and 95%, respectively with rupture of splenic artery during pregnancy [2].

Management of renal haemorrhage should be individualised based on renal function, nature of the disease and maternal-foetal status. This may involve simultaneous caesarean section and radical nephrectomy, conservative management to achieve vaginal delivery, selective arterial embolisation or partial nephrectomy in the second trimester [2].

Sherer, *et al.* [5]. reported a case of extensive spontaneous retroperitoneal hemorrhage due to heparin anticoagulation. Decision was to treat the patient conservatively with intravenous fluid hydration. The hematoma was self-limited and did not require any endovascular or surgical intervention.

Conservative management is usually preferred for haemodynamically stable patients with no active bleeding [6]. In a non-expanding haematoma without pressure symptoms and haemodynamically stable patient remaining conservative is the management of choice [7].

Urgent high quality CT imaging is mandatory to document the type, site and extent of the Haematoma [6]. There is growing trend in the use of endovascular techniques as an alternative to open surgery in the management of RH. The main options are selective intra-arterial embolisation or stent-grafts to stop the bleeding [6].

## Conclusion

According to the literature, therapeutic behavior in patients with spontaneous retroperitoneal haematoma depends on the haemodynamic status of the patient.

Close monitoring is essential and in the face of an unfavorable evolution, surgical intervention can improve results. Spontaneous retroperitoneal hematoma can occur without an evident cause, therefore,

obstetrians must considerate this infrequent but possible complication.

## References

1. Bhosale A, Fonseca M, Nandanwar YS (2008) A rare case of retroperitoneal haematoma complicating pregnancy. *Bombay Med J* 50: 316-7.
2. Rafi J, Muppala H (2010) Retroperitoneal haematomas in obstetrics: literature review. *Arch Gynecol Obstet* 281: 435-41.
3. Rafi J, Muppala H (2014) Conservative management of massive puerperal spontaneous onset retroperitoneal psoas muscle haematoma following normal vaginal delivery. *Obs case reports*.
4. Faisal Alturki, Vincent Ponette, Louis-Martin Boucher (2018) Spontaneous Retroperitoneal Hematomas Following Uncomplicated Vaginal Deliveries: A Case Report and Literature Review. *J Obstet Gynaecol Can* 40: 712-5
5. Sherer DM, Dayal AK, Schwartz BM (1999) Extensive spontaneous retroperitoneal hemorrhage: an unusual complication of heparin anticoagulation during pregnancy. *J Matern Fetal Med* 8: 196-9.
6. Chan YC, Morales JP, Reidy JF (2008) Management of spontaneous and iatrogenic retroperitoneal haemorrhage: conservative management, endovascular intervention or open surgery? *Int J Clin Pract* 62: 1604–13.
7. Harma M, Harma M, Ozturk A, Gungen N (2004) Spontaneously resolved post-caesarean giant retroperitoneal haematoma: a case report. *Int J Gynecol Obstet* 2004: 3.

**Submit your manuscript to a JScholar journal and benefit from:**

- § Convenient online submission
- § Rigorous peer review
- § Immediate publication on acceptance
- § Open access: articles freely available online
- § High visibility within the field
- § Better discount for your subsequent articles

Submit your manuscript at  
<http://www.jscholaronline.org/submit-manuscript.php>