

Zavras-Kounis Syndrome Simultaneously with Reactional Myoclonus Post-Streptokinase in Covid-19 Inducing Myocardial Infarction; Interpretation and Serious Implications

Yasser Mohammed Hassanain Elsayed*

Critical Care Unit, Kafr El-Bateekh Central Hospital, Damietta Health Affairs, Egyptian Ministry of Health Damietta, Egypt

*Corresponding authors: Elsayed YMH, Critical Care Unit, Kafr El-Bateekh Central Hospital, Damietta Health Affairs, Egyptian Ministry of Health Damietta, Egypt, Tel: 00201141292365, Email: dryaser24@yahoo.com

Received Date: March 01, 2022 Accepted Date: May 03, 2022 Published Date: May 05, 2022

Citation: Elsayed YMH (2022) Zavras-Kounis Syndrome Simultaneously with Reactional Myoclonus Post-Streptokinase in Covid-19 Inducing Myocardial Infarction; Interpretation And Serious Implications. J Vir Res Adv Vac 3: 1-7.

Abstract

Rationale: Drug-associated adverse effects are one of the most important entities in clinical medicine. Involuntary movements may have a dynamic serious impact on myocardial muscle. Myoclonus is well as abnormal involuntary movements with a distinct description. Myoclonus is a physical trauma and stress for coronary arteries. Physical and mechanical stress may be causing coronary artery spasm. Drug-inducing allergic angina, allergic coronary artery spasm, and allergic myocardial infarction are renowned as Zavras-Kounis syndrome. Streptokinase is a still-known effective thrombolytic in myocardial infarction. There is a correlation between COVID-19 infection and myocardial infarction.

Patient concerns: A 70-year-old married, farmer, smoker, Egyptian male patient was admitted to the critical care unit with acute inferior myocardial infarction and suspected COVID-19 pneumonia. An interlacing generalized myoclonus and allergic coronary artery spasm occurred.

Diagnosis: Reactional myoclonus with allergic coronary artery spasm post-streptokinase in COVID-19 inducing myocardial infarction.

Interventions: Electrocardiography, oxygenation, streptokinase intravenous infusion, and echocardiography.

Outcomes: Reactional generalized myoclonus with coronary artery spasm had happened during-streptokinase infusion but the dramatic response was the result.

Lessons: Dramatic clinical and electrocardiographic response after using the traditional anti-allergic signifying its role and suggest the diagnosis of Zavras-Kounis syndrome. The presence of continuing generalized myoclonus movements with the disappearance of coronary artery spasm after stoppage may be directed to the myoclonus cause. Streptokinase causing gen-

eralized myoclonus movements previously unknown, so it is a new recording adverse effect finding. The presence of involuntary movements, COVID-19 pneumonia, myocardial infarction, elderly, and cigarette smoking are prognostic factors for the severity of the disease.

Keywords: Reactional Myoclonus, Allergic Coronary Artery Spasm, Zavras-Kounis Syndrome, Streptokinase, COVID-19 inducing Myocardial Infarction

Abbreviations: IMI: Inferior Myocardial Infarction; COVID-19: Coronavirus disease 2019; ECG: Electrocardiogram; ICU: Intensive Care Unit; MI: Myocardial Infarction; O₂: Oxygen; SGOT: Serum Glutamic-Oxaloacetic Transaminase; SGPT: Serum Glutamic-Pyruvic Transaminase; VR: Ventricular Rate STEMI: ST-Segment Elevation Myocardial Infarction

Introduction

Allergic angina pectoris or Kounis–Zavras (KS) syndrome is defined as the simultaneous existence of chest pain and allergic reactions associated with clinical and workup signs of typical angina pectoris caused by inflammatory mediators emitted during the allergic episode [1,2]. KS was originally delineated by Kounis and Zavras in 1991 [3]. KS syndrome comprises all clinical-spectrum of acute cardiac ischemia, from angina pectoris to acute myocardial infarction (AMI) in synchronization with an “allergic” (hypersensitivity, anaphylactic, or anaphylactoid) reaction [1,2]. Clinical symptoms are mostly due to coronary artery spasm (CAS) [1,2]. Angina is clinically more common than AMI [4]. While the precise pathophysiological mechanisms are unknown, but inflammatory mediators produced in the framework of anaphylactic reactions like to be the primary mechanism resulting in allergic AMI [4]. Three variants of KS have been described. In Variant-I (the most frequent variant, 72.6%), the release of inflammatory mediators causes CAS with or without an increase of cardiac enzymes and troponins. In variant-II (22.3%), the produced inflammatory mediators, concurrently yield CAS with plaque rupture manifesting as AMI. Variant-III (5.1%) involves patients with stented coronary artery thrombosis due to an allergic reaction. The treatment of the allergic reaction may be helpful for the patients with the KS Variant-I which, by itself can curing the cardiac symptoms [5]. To overcome the acute phase, these patients require corticosteroids, anti-histamines (both H₁- and H₂-blockers), fluid resuscitation, and eventually epinephrine, and not the standard therapy for MI (e.g. aspirin, heparin, β -blockers (BB), angiotensin-converting enzyme (ACE) inhibitors, statins, percutaneous coronary intervention (PCI), stent implantation) [6]. Myoclonus is defined as a complex hyperkinetic arrhythmic movement disorder with abrupt, transient, shock-like, involuntary jerks affecting a separated muscle or a group of muscles [7]. Nonetheless, myoclonus can be positive if

there are fluxes of the muscular activity or negative if there is the incompetence of muscular activity. It may be focal, multifocal, or generalized. Moreover, myoclonus can be categorized into clinical, etiological, and anatomical. It may be present at rest, during voluntary movement, or post-inducing stimuli e.g., sensory, visual, auditory, or emotional cues. The diagnosis of reversible types of myoclonus is a pivotal step for management [7]. Streptokinase (SK) is an enzyme and thrombolytic drug [8]. As a medication, it is used to break down clots in some cases of AMI, acute pulmonary embolism (APE), and arterial thromboembolism [9]. The most frequent side effects include nausea, bleeding, hypotension, and allergic reactions [9]. Multiple mechanisms have been suggested for cardiac damage in the COVID-19 epidemic. The systemic inflammatory response in severe COVID-19 is the producing high levels of cytokines causing cytokine-release syndrome (CRS) that can injure multiple tissues, involving vascular endothelium and cardiac myocytes [10]. Plaque rupture causes acute myocardial infarction due to the systemic inflammation and catecholamine surge in this disease [11,12]. Coronary thrombosis also has been identified as a possible cause of AMI in COVID-19 patients [13].

Case Presentations

A 70-year-old married, farmer, smoker, Egyptian, male patient was admitted to the intensive care unit (ICU) with acute severe chest pain. Profuse sweating, tachypnea, generalized body aches, and fatigue were the associated symptoms. Chest pain was anginal, compressible, intolerable, and progressive. He gave a history of fever, cough, and generalized body aches one week ago. The patient is a currently heavy smoker (at least 40 cigarettes for about 35 years). He denied a history of cardiovascular diseases, the same attack, drugs, or any other special habits. There was a recent positive history for contact with a COVID-19 confirmed patient. Informed consent was taken. Upon general

physical examination; generally, the patient was anxious, severe sweaty, had cold extremities, with a regular heart rate of 60 bpm, blood pressure of 110/70 mmHg, respiratory rate of 24 bpm, the temperature of 37 °C, and pulse oximeter of O₂ saturation of 93%. No more relevant clinical data were noted during the clinical examination. Urgent and serial ECG tracings were done in the ICU. The initial ECG tracing was done on the presentation showing an acute inferior (II, III, and aVF) ST-segment elevation myocardial infarction (STEMI) and reciprocal ST-depression changes in leads (I, aVL, and V₂-V₅). (Figure 1A). The second right-side ECG tracing using V₃R and V₄R was done within 3 minutes of the above initial tracing. It is showing no right ventricular involvement (Figure 1B). The third ECG tracing was done within 20 minutes of the initiation of streptokinase IVI showing good resolution in the inferior ST-segment elevation with normalization of most reciprocal ST-depression changes in leads (I and V₂-V₅). But there are a Wavy triple sign or Yasser's sign in I and II leads (Figure 1C). Aspirin 4 chewable oral tablet (75 mg), clopidogrel 4 oral tablet (75 mg), O₂ inhalation was given (100%, by nasal cannula, 5L/min) were the emergency given medications. Pethidine HCL 100 mg was given on intermittent IV doses. Streptokinase IVI (1.5 million units over 60 minutes) was given. Involuntary movements had happened 40 minutes of the initiation of streptokinase IVI and continued for about 60 minutes without cessation. The patient was managed urgently in the intensive care unit with high flow 100% O₂ inhalation, IV hydrocortisone 200mg, IV chlorpheniramine maleate 10 mg, and IV dexamethasone 8 mg. ECG tracing was done within 40 minutes of the initiation of streptokinase IVI and during the occurrence of involuntary movements showing reversible inferior (II, III, and aVF) ST-segment elevation myocardial infarction (STEMI) and reciprocal ST-depression changes in leads (I, aVL, and V₂-V₅). (Figure 1D). ECG tracing was done within 30 minutes after the cessation of streptokinase IVI and after being given anti-allergic showing slight improvement in the above inferior (II, III, and aVF) ST-segment elevation myocardial infarction and reciprocal ST-depression changes in leads (I, aVL, and V₂-

V₄). (Figure 1E). ECG tracing was done within 9 hours after the above streptokinase IVI reaction and management showing nearly total improvement in the above inferior changes. There are evolutionary T-wave inverted changes. (Figure 1F). The measured random blood sugar was 137 mg/dl. The troponin test was positive (2.26 ng/L). CBC, SGOT, SGPT, serum creatinine, and blood urea were within normal. D-dimer was high (876 ng/ml). CRP was high (28 g/dl). Ferritin was high (511 ng/ml). LDH was high (593U/L). Chest CT without contrast was done within 5 days of the presentation showing bilateral patchy ground-glass pulmonary consolidation in the peripheral, basal, and posterior segments. There is mild to moderate basal pleural effusion (Figure 2A). Plain chest x-rays film was done within 5 days of the presentation showing bilateral patchy ground-glass pulmonary consolidation (Figure 2B). The echocardiographic report showed previously were done for follow-up showing hypokinetic inferior and basal inferoseptal segments with mild to moderate mitral regurgitation, mild aortic regurgitation, mild tricuspid regurgitation, and grade I diastolic dysfunction with EF of 60%. No more workup was done. The patient was maintained treated with cefotaxime; (1000 mg IV every 8hours), azithromycin (500 mg PO single daily dose), oseltamivir (75 mg PO twice daily only for 5 days), and paracetamol (500 mg IV every 8 hours as needed). SC enoxaparin 80 mg twice daily), aspirin tablet (75 mg, once daily), clopidogrel tablet (75 mg, once daily), and hydrocortisone sodium succinate (100 mg IV every 12 hours; was tapered with time) was added for 5 days. The patient was daily monitored for temperature, pulse, blood pressure, and O₂ saturation. Zavras-Kounis syndrome simultaneously with reactional myoclonus post-streptokinase in COVID-19 inducing myocardial infarction was the most probable diagnosis. The patient was discharged on the fifth day after clinical and electrocardiographic improvement. The patient was continued: aspirin tablet (75 mg, once daily), clopidogrel tablet (75 mg, once daily), and atorvastatin (40 mg once daily). The patient was planned for future cardiac catheterization with recommended cardiovascular, pulmonology, and infectious disease follow-up.

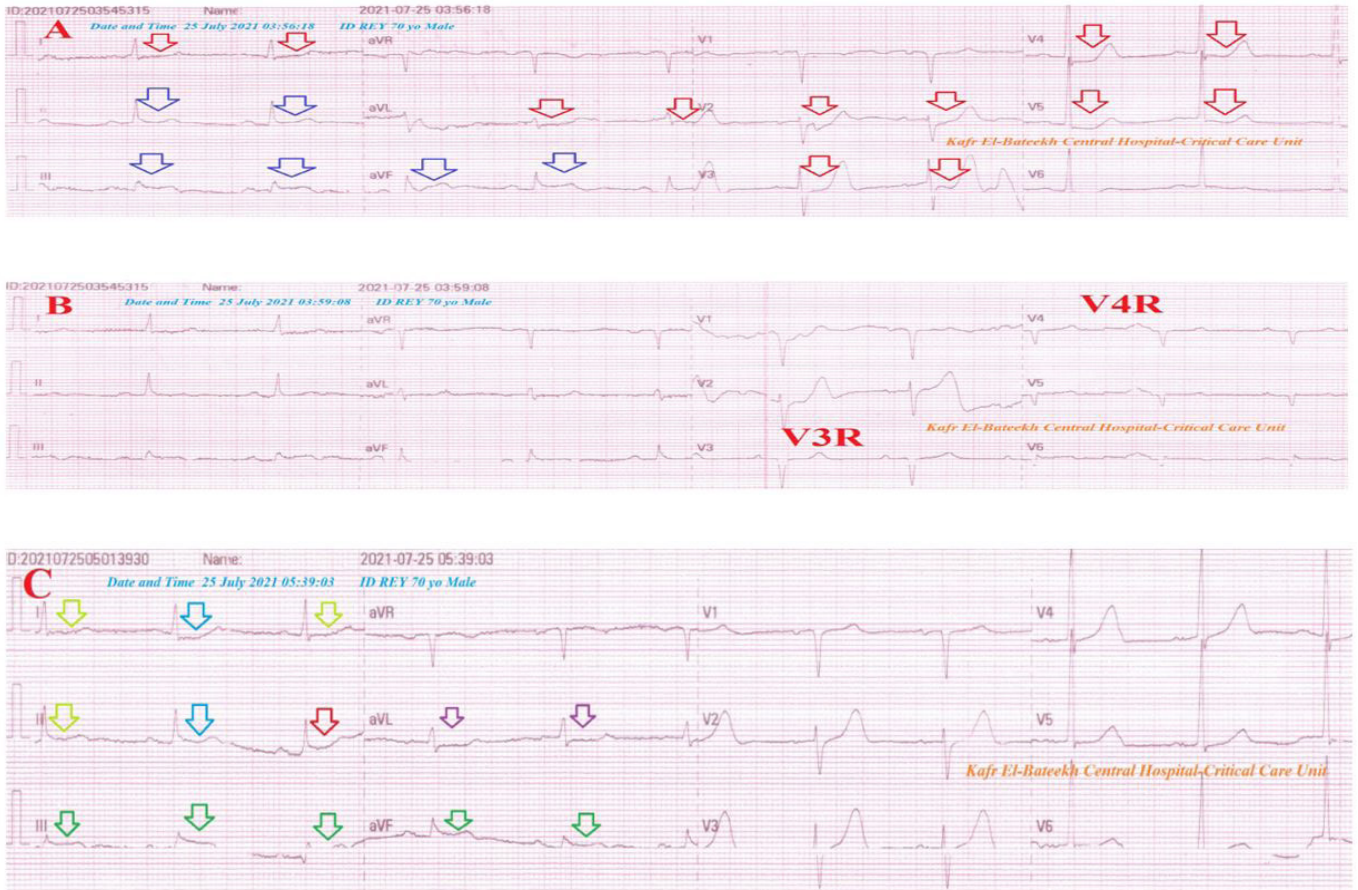


Figure 1 A-C: Serial ECG tracings; A. initial tracing was done on the presentation in the ICU showing an acute inferior (II, III, and aVF; red arrows) ST-segment elevation, myocardial infarction (STEMI) and reciprocal ST-depression changes in leads (I, aVL, and V2-V5; blue arrows). B. tracing using V34 and V4R was done within 3 minutes of the above initial tracing. It is showing no right ventricular involvement. C. tracing was done within 20 minutes of the initiation of streptokinase IVI showing good resolution in the inferior ST-segment elevation with normalization of most reciprocal ST-depression changes in leads (I and V2-V5). There is a Wavy double sign or Yasser's sign in I (lime and light blue arrows). and Wavy triple sign or Yasser's sign-in II leads (lime, light blue, and red arrows).

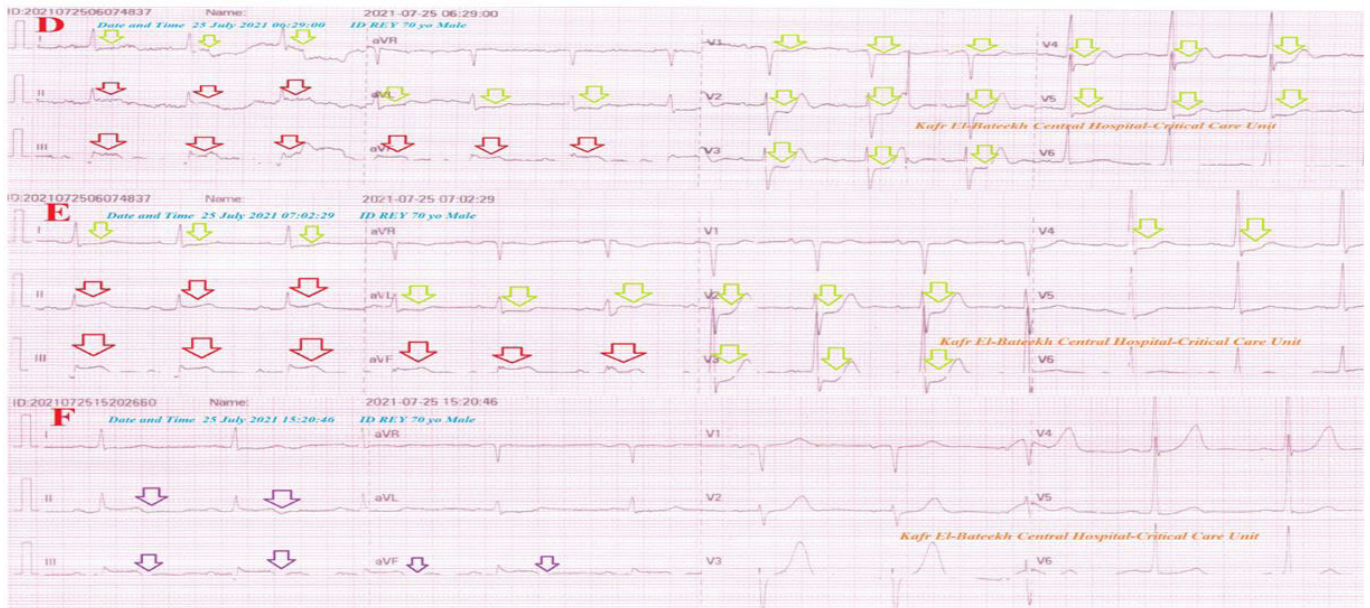


Figure 1 D-F: D. tracing was done within 40 minutes of the initiation of streptokinase IVI and during the occurrence of involuntary movements showing reversible inferior (II, III, and aVF; red arrows) ST-segment elevation myocardial infarction (STEMI) and reciprocal ST-depression changes in leads (I, aVL, and V2-V5; lime arrows). E. tracing was done within 30 minutes after the cession of streptokinase IVI and after given anti-allergic showing slight improvement in the above inferior (II, III, and aVF; red arrows) ST-segment elevation myocardial infarction and reciprocal ST-depression changes in leads (I, aVL, and V2-V4; lime arrows). F. tracing was done within 9 hours after the above streptokinase IVI reaction and management showing nearly total improvement in the above inferior changes. There are evolutionary T-wave inverted changes (pink arrows).

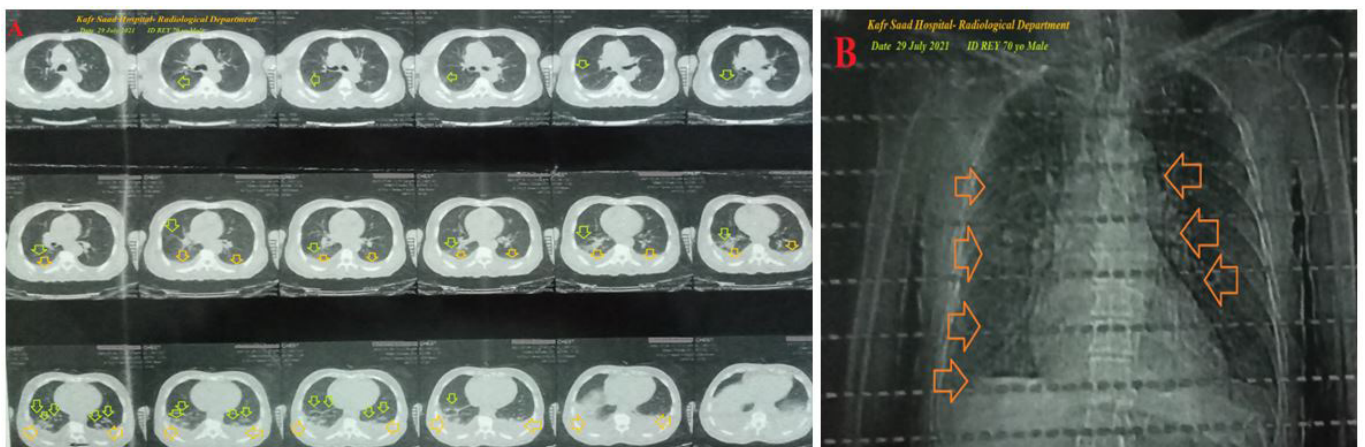


Figure 2 A- Chest CT without contrast was done within 5 days of the presentation showing bilateral patchy ground-glass pulmonary consolidation in the peripheral, basal, and posterior segments (lime arrows). There is mild to moderate basal pleural effusion (orange arrows). **B-** plain Chest XR film was done within 5 days of the presentation showing bilateral patchy ground-glass pulmonary consolidation (orange arrows).

Discussion

Overview

- A 70-year-old married, farmer, smoker, Egyptian male patient was admitted to the ICU with acute inferior myocardial infarction (IMI) and suspected COVID-19 pneumonia. An interlacing generalized myoclonus and allergic CAS occurred.

- The primary objective for my case study was the presence of a patient who presented with acute inferior ST-segment elevation myocardial infarction (STEMI) and suspected COVID-19 pneumonia with interlacing generalized myoclonus and allergic CAS in the POC.

- The secondary objective for my case study was the question of; How did you manage the case at home?

- There is an existence of lonely acute inferior STEMI ST-segment elevation myocardial infarction with no right ventricular involvement. This acute myocardial infarction was indicated for immediate thrombolytic.

- The presence of attack of generalized myoclonus nearly had happened during the halving infusion dose of streptokinase.

- There is good resolution in the inferior ST-segment elevation with normalization of most reciprocal ST-depression changes in leads occurred within 20 minutes of the initiation of streptokinase IVI.

- There is a recurrent an acute inferior (II, III, and aVF) ST-segment elevation myocardial infarction (STEMI) and reciprocal ST-depression changes in leads (I, aVL, and V2-V5) during myoclonus attack and reversed with the traditional anti-allergic medications. This reaction is indicating that is allergic in origin and allergic coronary artery spasm or Zavras-Kounis syndrome.

- Dramatic clinical and ECG reversal of ST-segment deviations during streptokinase IVI with myoclonus is a good prognostic sign.

- The presence of pleural effusion is either reflecting pulmonary embolization associated with COVID-19 pneumonia or weak myocardial muscle due to myocardial infarction.

- Rigors and convulsions are the most possible differential diagnosis for the current case study.

- I can't compare the current case with similar conditions. There are no similar or known cases with the same management for near comparison.

- The only limitations of the current study are the absence of psychiatrist consultation at the time of the myoclonic attack.

Conclusion and Recommendations

- Dramatic clinical and electrocardiographic response after using the traditional anti-allergic signifying its role and suggest the diagnosis of Zavras-Kounis syndrome.

- The presence of continuing generalized myoclonus movements with the disappearance of coronary artery spasm after stoppage may be directed to the myoclonus cause.

- Streptokinase causing generalized myoclonus movements previously unknown, so it is a new recording adverse effect finding.

- The presence of involuntary movements, COVID-19 pneumonia, elderly, smoking are prognostic factors for the severity of the disease.

Acknowledgment

I wish to thank the team of nurses in the critical care unit in Kafr El-Bateekh Central Hospital who make extra-ECG copies for helping me. Also, I want to thanks my wife to save time and improving the conditions for supporting me.

Conflicts of Interest

There are no conflicts of interest.

References

1. Kounis NG (2006) Kounis syndrome (allergic angina and allergic myocardial infarction): a natural paradigm? *Int J Cardiol* 7: 7-14.
2. Fassio F, Almerigogna F (2012) Kounis syndrome (allergic acute coronary syndrome): different views in allergologic and cardiologic literature. *Intern Emerg Med*. 7: 489-495.
3. Elsayed YMH (2019) Anti-shock Measures relieved Bee-Sting Anaphylaxis- Induced Kounis Type I Syndrome: A case Report. *Biomed J Sci & Tech Res* 22: 16990-16993.
4. Campo G, Pavasini R, Pollina A, Petrini L, Ferrari R (2012) Kounis-Zavras syndrome presenting with ventricular arrhythmias and cardiogenic shock. *J Cardiol Cases* 7: e74-e77.
5. Abdelghany M, Subedi R, Shah S, Kozman H (2017) Kounis syndrome: A review article on epidemiology, diagnostic findings, management and complications of allergic acute coronary syndrome. *Int J Cardiol*. 232: 1-4.
6. Cevik C, Nugent K, Shome GP, Kounis NG (2010) Treatment of Kounis syndrome. *Int J Cardiol* 143: 223-226.
7. Elsayed YMH (2020) Amlodipine-induced myoclonus with subsequent physical coronary artery spasm. *WW Med* 2: 52-57.
8. Sikri N, Bardia A (2007) A history of streptokinase use in acute myocardial infarction. *Tex Heart Inst J* 34: 318-27.
9. World Health Organization, Stuart, Marc C, Kouimtzi, Maria & Hill, Suzanne (2009) WHO model formulary 2008 / editors: Marc C. Stuart, Maria Kouimtzi, Suzanne R. Hill. *World Health* 291-292.
10. Basu-Ray I, Almaddah Nk, Adeboye A, Michael PS (2022) Cardiac Manifestations of Coronavirus (COVID-19).
11. Xiong TY, Redwood S, Prendergast B, Chen M (2020) Coronaviruses and the cardiovascular system: acute and long-term implications. *Eur Heart J* 41: 1798-1800.
12. Schoenhagen P, Tuzcu EM, Ellis SG (2002) Plaque vulnerability, plaque rupture, and acute coronary syndromes: (multi)-focal manifestation of a systemic disease process. *Circulation* 106: 760-762.
13. Dominguez-Erquicia P, Dobarro D, Raposeiras-Roubin S, Bastos-Fernandez G, Iñiguez-Romo A (2020) Multivessel coronary thrombosis in a patient with COVID-19 pneumonia. *Eur Heart J* 41: 2132.

Submit your manuscript to a JScholar journal and benefit from:

- ☞ Convenient online submission
- ☞ Rigorous peer review
- ☞ Immediate publication on acceptance
- ☞ Open access: articles freely available online
- ☞ High visibility within the field
- ☞ Better discount for your subsequent articles

Submit your manuscript at
<http://www.jscholaronline.org/submit-manuscript.php>