

## Magnetic Resonance Imaging in Cervical Cancer Management In Principal Hospital in Dakar (Senegal)

Thierno Oumar SOKO<sup>1\*</sup>, Auster Codjo AYI MEGNANGLO<sup>2</sup>, Abdou Rahmane Ndiaye<sup>1</sup>, Ndèye Isseu AMAR<sup>1</sup>, Mame Diarra Bouso NDAW<sup>1</sup>, Aminata DIACK<sup>1</sup>, Moustapha Diallo<sup>1</sup>, Massamba DIOP<sup>1</sup>, Amat FALL<sup>1</sup>, Cheikh Tidiane DIOUF<sup>1</sup>, Ababacar MBENGUE<sup>1</sup>, and Ibrahima Cissé DIAKHATE<sup>1</sup>

<sup>1</sup>Radiologist at Hôpital Principal, Dakar, Senegal

<sup>2</sup>Radiologist at HIA Cotonou, Bénin

\*Corresponding author: Thierno Oumar SOKO, Department of Medical Imaging Dakar Principal Hospital, Dakar, Senegal, Tel: +221776083175, E-mail: tosoko@gmail.com

Received Date: April 23, 2021 Accepted Date: May 23, 2021 Published Date: May 25, 2021

Citation: Thierno Oumar SOKO (2021) Magnetic Resonance Imaging in Cervical Cancer Management In Principal Hospital in Dakar (Senegal). J Womens Health Gyn 8: 1-8.

### Abstract

**Objective:** To describe the results of Magnetic Resonance Imaging (MRI) in patients screened for uterine cervical cancer.

**Patients and Methodology:** A retrospective descriptive study was conducted from March 2011 to July 2014, at the Medical Imaging Department of *Hôpital Principal*. The study featured MRI patients screened for uterine cervical cancer with a 1.5 Siemens® Avanto® protocol comprising at least one 3-plan T2-weighted sequence, a diffusion-weighted sequence and a T1-weighted sequence with fat saturation before and after Gadolinium injection.

**Results:** 61 patients were screened, including 45 (60.85%) for pretreatment staging, 13 for post-surgical testing and 3 for postoperative testing (PRT) or chemoradiotherapy (CRT). The average age was 56 years [34 - 78 years]. Based on the FIGO MRI classification, 31.14% of the cases (n = 19) were found to have stage IIIB cervical cancer, 27.86% had stage IIB (n = 17), 11.47% had IVA (n = 7) and 11.47% had stage I. Eight out of the thirteen patients assessed for post-surgery alone had a local recurrence; 2 had fibrosis, 2 had no visible tumour, and one case of textiloma was detected. The 3 post-PRT or CRT alone cases revealed no residual tumour.

**Conclusion:** MRI detects an advanced tumour in most of our patients seen for a cervical cancer assessment, including parametrial involvement which classifies the patient at the FIGO IIB stage wherefrom prognosis is poor. Prevention remains possible through early detection and young girls' immunization.

**Keywords:** Cervix Uteri Neoplasm; MRI; Senegal

**List of abbreviations:** MRI: Magnetic Resonance Imaging; PRT: Post-Operative Testing; CRT: Chemoradiotherapy ERT: External Radiotherapy; FIGO: International Federation of Gynecology and Obstetrics

## Introduction

A Cervical cancer is the third most common cancer in women and the second most common gynaecological cancer. In many developing countries, it is the leading cause of cancer mortality in women.

As far as we know, since MRI equipment is available in Senegal in year 2006, only one study has been conducted in Senegal concerning the role of MRI in this disease.

MRI, a modern medical imaging tool, is increasingly available in developing countries and should improve cancer patients treatment and care by providing a comprehensive initial extension assessment and optimal post-therapeutic monitoring.

The authors of this article share their MRI experience in cervical cancer by describing lesions based on the 2009 FIGO classification applied to MRI, and the resulting therapeutic implications in the field of medical practice in an underdeveloped country.

## Patients and Methods

This is a retrospective descriptive mono-centric study conducted over 41 months (from March 2011 to July 2014) in the Medical Imaging Department of *Hôpital Principal* in Dakar. This Level III Army Training Hospital has a platform with a high-field MRI unit (1.5 Tesla) purchased in 2007, two multi-section scanners (64 and 16 bars), two Doppler ultrasound rooms and a digital radiology unit.

All patients seen in the MRI Department for cervical cancer during the study period were included in the study. Patients without T2-weighted sequence and cases without prescription or complete examination report were excluded.

Examinations were performed on a 1.5 Tesla Siemens® Avanto® magnet with a phased array surface antenna, by means of a protocol comprising at least a T2- weighted TSE sequence in 4 mm sections covering the pelvis in the sagittal, coronal and transverse axial planes, perpendicular to the tumour axis; a diffusion sequence; a T1-weighted sequence with fat saturation, with and without contrast injection in dynamic acquisition. Vaginal markings were not systematic.

The data, collected from the MRI prescription and the examination report were as follows: the patient's age, the indication for the examination, and the following MRI characteristics: local tumour extension based on the criteria of the 2009 FIGO classification, and presence of locoregional adenomegalias.

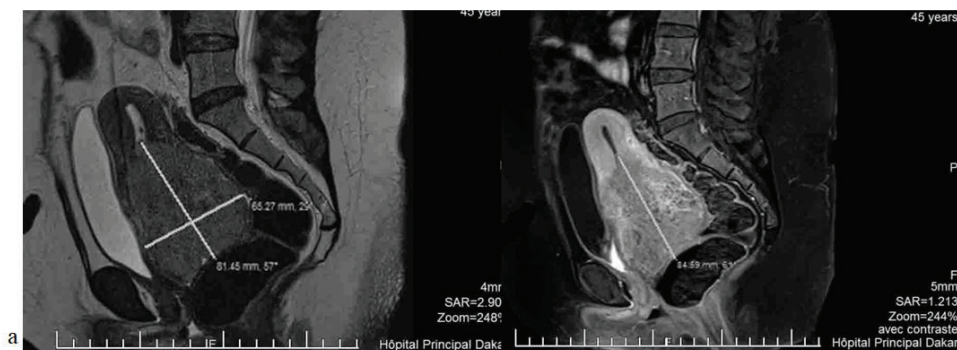
The sample size was calculated using Microsoft® Excel®. Because the patients were not questioned on this subject in our department, risk factor assessment has not been established.

## Results

61 patients were observed for cervical cancer in the MRI Department over 41 months. This averaged 18 women per year. 45 of these patients were seen for initial extension assessment, 13 for post-surgical monitoring and 3 for post external radiotherapy (ERT) or radio chemotherapy (RCT) monitoring. The average age of the patients was 56 years [34-78 years]. Table 1 shows the patients' age distribution.

**Table 1:** Patient Age Distribution

Age	Number	Percentage
< 35 years	1	1.63%
35 to 45 years	13	21.31%
46 to 55 years	16	26.22%
56 to 65 yrs	15	24.59%
66 to 75 years	8	13.11%
> 75 years	5	8.19%
Not specified	3	4.91%



**Figure 1:** T2-weighted Sagittal Section (a) and T1-weighted Fat Sat (b) injected with a tumour of larger than 4cm limited to the cervix

The tumour size was larger than 4 cm in 42 cases (68.85%) and smaller than 4 cm in 11 cases (18.03%). This size was not specified in 8 cases.

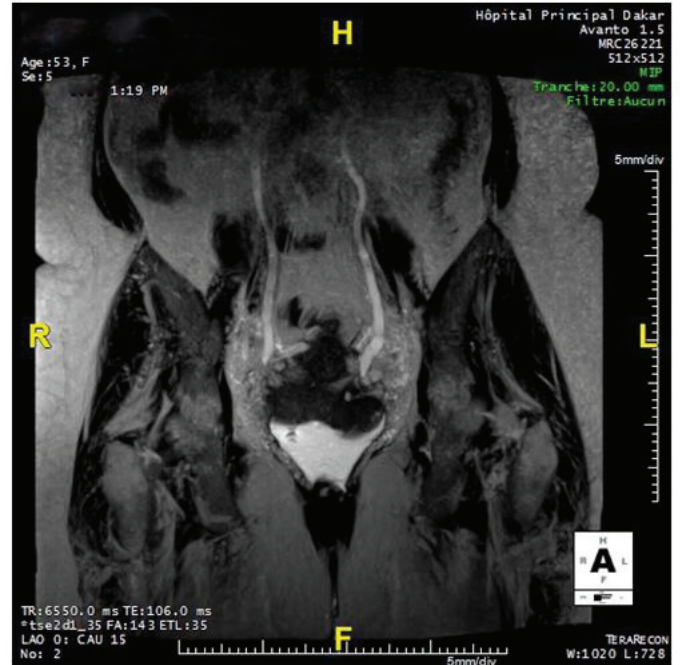
34 (75.5%) of the 45 women seen for initial extension assessment had a tumour larger than 4 cm and 8 (17.7%) had a tumour size smaller than 4 cm. In 3 cases, the tumour size was not specified on the MRI report.

With respect to tumour extension (Table II), there was some proximal involvement of the vagina in 16 cases (26.22%) and distal involvement in 21 cases (34.42%). Parametrial damage was found in 44 cases or 72.13% (Figure 2).

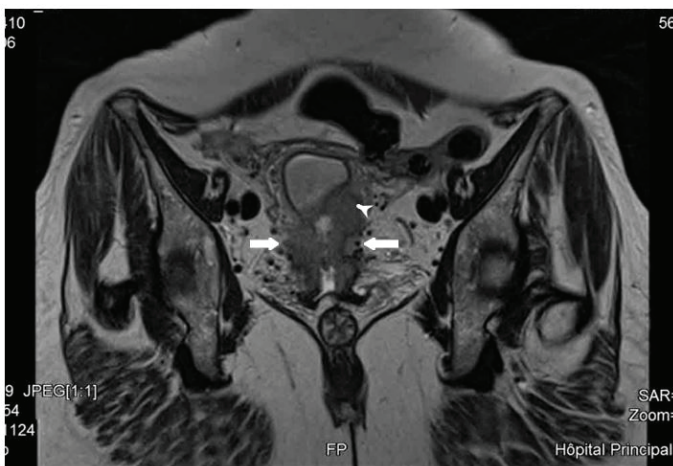**Table 2:** Tumour Extension Based on Sites Affected

Sites	Number	Percentage
2/3 proximal vagina	16	26.22%
1/3 distal vagina	21	34.42%
Paramters	44	72.13%
Bladder	12	19.67%
Rectum	12	19.67%
Hydronephrosis	13	21.31%
Pelvic wall	1	1.64%
Adenomegalies	35	57.37%
Metastases	3	4.91%

Adenomegalies (Figure 4) were found in 35 cases, which accounts for 57.37%. Lymph node hypertrophy was found in 79.41% of patients seen for an initial extension assessment, with a tumour larger than 4 cm and 12.5% of patients with tumours smaller than 4 cm.



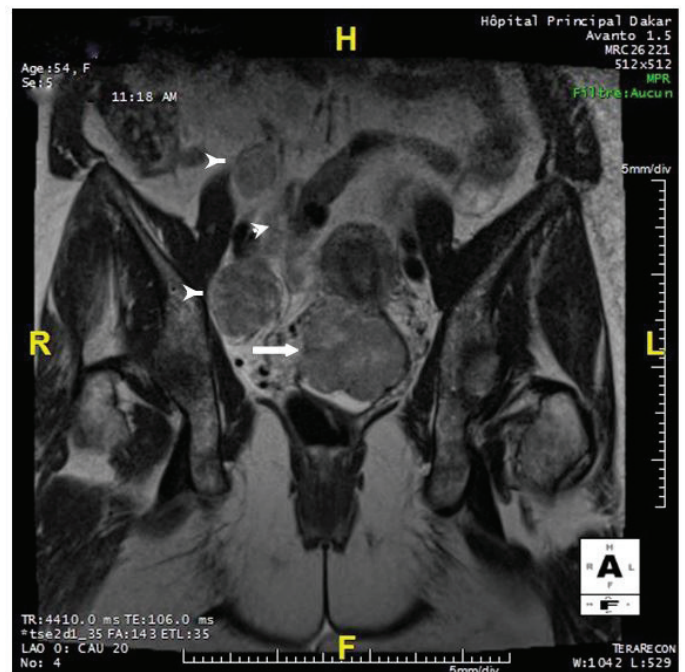
**Figure 3:** Bilateral Ureteral Ailation (Arrow) Upstream of a Cervical Tumour Invading the Parameters



**Figure 2:** T2-weighted Coronal Section of a Tumour with Extension to the My- ometrium (Arrowhead) and Parameters (Solid Arrows)

Ureteral dilatation (Figure 3) was present in 13 patients (21.31%) while unilat- eral dilatation was observed in 9 cases. Pelvic wall involvement was found in only one case.

Using the FIGO MRI classification, stage IIIB was found in 19 cases (31.14%), stage IIB in 17 cases (27.86%) and stage IV in 10 cases (16.38%). Table III summarizes the FIGO MRI stages encountered.

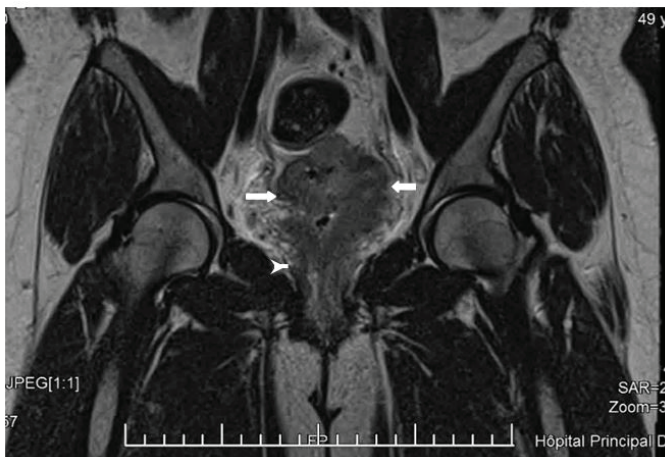


**Figure 4:** T2-weighted Coronal Section of a Cervical Tumour, with Extension to the Right Parameter (Solid Arrow) and Right Iliac Lymph Node Flow (Arrow Heads)

Bladder invasion was noted in 12 cases (19.67%) and as many cases of rectal involvement were found. There were 5 cases with simultaneous involvement to the bladder and rectum.

Three cases (4.91%) of secondary hepatic localization were found. Tumour extension based on affected sites is summarized in Table 3.

MRI for post-therapeutic control found 8 cases of recurrence (Figure 5), and two cases of total remission; the examination also found one case of textiloma and two cases of fibrosis



**Figure 5:** T2-weighted Coronal Section of a Cervical Tumour with Extension to the Parametria (Arrows) and Vagina (Arrow Head)

**Table 3:** Distribution of Patients Based on FIGO MRI Stages

FIGO MRI Stage	Number	Percentage
Stage I	7	11.47%
Stage IIA	1	1.64%
Stage IIB	17	27.86%
Stage IIIA	2	3.27%
Stage IIIB	19	31.14%
Stage IVA	7	11.47%
Stage IVB	3	4.91%
No tumour	3	4.91%
Fibrosis	2	3.27%
Total	61	100%

## Discussion

Cervical cancer is the 2nd most common cancer in women worldwide and the leading cause of cancer mortality in women in underdeveloped countries [1].

According to the World Health Organization (WHO), there were 540,000 new cases of cervical cancer causing 275,000 deaths in 2010, with 85% of cases observed in developing coun-

tries [2]. In Senegal, there are about 1,197 new cases of cervical cancer causing 795 deaths every year [3].

The therapeutic strategy is based on the FIGO classification modified in 2009 and MRI plays a key role in both the initial pre-treatment assessment and post-therapeutic monitoring.

Our series includes 61 cases recorded over 41 months. For comparison, Diop et al. [5], in a study conducted at the Dakar University Hospital had collected 30 cases over 47 months. In the Maghreb, Felfel et al. [6] reported 14 cases over 2 years, Hadj Kacem et al. [7] about twenty, and Guesmi [8] 30.

Our patients' average age of 56 years is the same as that described by Heo et al. [9], but is higher than the average age of 51.1 years found by Hori et al. [10]. As for Diop et al. [5], they found an average age of 45.7 years. The most affected age group in our series is between 46 and 55 years with 26.22% of cases (n=16). In all these series, the patients were middle-aged women.

With respect to tumour size (which is part of the FIGO classification criteria), 42 of our patients - or 68.85% - had a tumour size larger than 4 cm. Among the patients seen for initial assessment, 34 had a tumour larger than 4 cm (75.5%), and only 8 had a tumour smaller than 4 cm (17.7%). In Diop et al. series [5], 23 women had a tumour size larger than 4 cm, which accounts for 92% of cases. Estimating tumour size has a therapeutic implication, as tumours larger than 4 cm require radiochemotherapy, whereas the treatment of tumours smaller than 4 cm, which is yet to be standardised, requires adjuvant and neo-adjuvant means [11,12]. Thus, based on tumour size estimate, it appears that 75.5% of the women seen for initial assessment in our series would not benefit from primary surgery. It should be noted that the MRI-measured size is correlated to the nearest 5 mm with surgery in 70 to 90% of cases [13]. However, MRI may overestimate this size in the event of peri-tumour inflammation, especially in injected T1-weighted sequences; the early injected sequence (30 seconds) and diffusion mean greater precision in this measurement and make it possible to visualize tumours of less than 1 cm in size [14].

Stage IIB FIGO was found in 48 of our patients (78.68%), while the earlier stages are present in only 8 cases, i.e. or 13.11%. This could be due to the patients reporting late to health facilities in sub-Saharan Africa. The therapeutic indication in the majority of these patients is that of neo-adjuvant or palliative radiochemotherapy. This FIGO IIB stage is determined by the invasion of at least one parameter invasion.

Parametrial damage was found in 44 of our patients (i.e. 72.13%), which is, therefore, a poor prognosis. In the Stenstedt et al. series [15] involving 183 125 surgery-treated patients and 58 patients treated by radiochemotherapy), parametrial involvement was found in 49 patients (84.48%) from the second group. MRI, with sensitivity ranging from 71 to 92% for the detection of stage IIB lesions and specificity between 82 and 93%, is superior to clinical examination [11]. Its negative predictive value is 94 to 100% [16,17], the best sign of a lack of parameter invasion being the visibility, over its entire circumference, of the hypo-intense pericervical fibrous ring in T2-weighted sequences.

In our series, the most common FIGO stage encountered in MRI was Stage IIIB with 19 cases or 31.14%. In the Diop et al. series [5], however, the most frequent FIGO stage was IIB with 56% of cases, while Heo et al. [9] identified the IIB stage in 29 cases out of 42 patients (69.04%), and Hori et al. [10] reported the IB1 stage 17 times (54.8%). Therefore, it seems that most of our patients came to late for surgical management.

The sensitivity of MRI for rectal or vaginal involvement (stage IV) is estimated to be between 71 and 100%, for a specificity of 88-91% [18]. However, the mere presence of bulbous edema does not warrant the classification of the tumour as a stage IV tumour [19]. Nineteen of our patients were in stage IV (31.14%) while in the Felfel et al. series [6] there were 2 cases of neighbouring organs involvement among their 14 patients. This could be related to patients in our regions reporting late to medical facilities for consultation.

With respect to lymph node involvement, the most commonly used sign is the measurement of the small lymph node axis with a threshold of 8 mm at the pelvic level and 10 mm at the lumbo-aortic level. 35 of our patients, or 57.37%, had local-regional adenomegalies. Diop et al. [5] found lymph node involvement in 60% of cases. Conversely, Heo et al. [9] found lymph node involvement in only 23.8% of cases (n=10) in their series of 42 patients.

Although lymph node involvement is considered an essential prognostic factor, it was not included in the FIGO classification before 2018 [20]. However, as much as MRI is effective in establishing a good lymph node mapping (especially on the diffusion sequence), it is not yet capable of affirming, with certainty, the metastatic nature of microganglions or the inflammatory or tumour nature of adenomegalies. Its sensitivity varies from 29 to 86 % while its specificity ranges from 78 to 99 % [11, 13, 21]. PET-scan is the choice examination in this area, especially at ad-

vanced stages [22, 23] where this lymph node involvement seems to be more frequent. It should be noted that adenomegalies were present in 79.41% of in our patients with a tumour larger than 4 cm, compared to 12.5% in patients with tumours smaller than 4 cm. In all cases, surgical biopsy remains more effective than imaging for lymph node assessment [24, 25].

#### The Specific Case of Post-treatment MRI Monitoring

Post-therapeutic monitoring aims to detect early locoregional recurrences, metastases, and treatment complications. It is mainly clinical but also biological and radiological. Recurrence is defined as an increase in primary lesion or the appearance of metastases within 6 months of treatment. Approximately 30% of patients monitored for invasive cervical could face a risk of death by recurrence [26], which occurs in 70% of cases in the form of remote metastases with or without association with locoregional recurrence, most often within 2 to 3 years post-treatment [27]. In our series, 8 out of the 13 patients seen for postoperative monitoring (61.53%) had a recurrence, 2 had fibrosis and a textiloma was found in one patient. Two examinations were considered normal and involved patients aged 39 and 52 who had a colpohysterectomy and a colpohysterectomy with lymph node cleansing, respectively. All the 3 cases of post-ERT control or RCT-only analysis, had recurrences.

Stenstedt [15] noted 21 cases of recurrence in the surgery-treated group (n=125) or 16.8%, and 23 recurrences (39.6%) in the radiochemotherapy group (n=58).

What makes MRI interesting is that it makes it possible able to differentiate post-therapeutic fibrosis from local recurrence [28]. It is a reference examination test with a 78% to 83% performance, a 65% positive predictive value and a 97% negative predictive value [29] for local recurrences. Diffusion MRI, with the measurement of the apparent diffusion coefficient (ADC), would be useful to differentiate between benign enhancements and tumour contrast enhancements observed during the first three months following irradiation. It may also be useful for the detection of a residual tumour or suspicious post-radiochemotherapy adenopathies and may be an alternative to positron emission tomography (PET) [30]. Local recurrences without pelvic wall involvement are potentially curable; close clinical monitoring is useful within 2 to 3 years following the initial treatment, with routine systematic imaging not recommended [19].

---

## Conclusion

MRI helped answer all the questions asked as part of the initial extension assessment or post-therapeutic evaluation of all our patients. The most affected age group in our series is between 46 and 55 years.

MRI is a key consideration and useful tool in cervical cancer management, even if most of our patients came at a late stage and could not be managed by surgery. Therefore, the best strategy against this scourge in developing countries is prevention, which is based on cervico-vaginal smear screening and vaccination against genital infection with Human Papilloma Virus, the main known risk factor associated with this type of cancer.

## References

1. Patel S, Liyanage SH, Sahdev A, Rackall AG, Reznik RH (2010) Imaging of endometrial and cervical cancer. *Insights Imaging* 1: 309-28.
2. Parkin DM, Bray F, Ferlay J, Pisani P (2005) Global cancer statistics, 2002. *CA Cancer J Clin* 55: 74-108.
3. WHO (2017) African Regional Network. Cervical cancer in the WHO African region: current situation and prospects, Regional Committee for Africa, Sixtieth session, Item 7.4 of the provisional agenda, Malabo, Equatorial Guinea.
4. Freeman SJ, Aly AM, Masako YK, Addley HC, Reinhold C, et al. (2012) The Revised FIGO Staging System for Uterine Malignancies: Implications for MR Imaging. *Radio Graphics* 32: 1805-27.
5. AD Diop, AA Dia, MMM Leye, O Thiam, A Mbengue, et al. (2015) Contribution of high-field MRI in the management of cervical cancer in Senegal. *J Afr Imag Méd* 3: 108-15.
6. Felfel M, Jaber M, Jabou M, Chammakhi R, Rajhi H, et al. (2008) Adenocarcinoma of the cervix versus mesenchymal tumors of the cervix: what is the benefit of MRI? *J Radiol* 89: 1532.
7. Kacem HH, Benayada B, Azizi Alaoui J, Latib R, Chami I, Boujida MN, et al. (2008) Contribution of MRI in cervical cancer. *J Radiol* 90: 1504.
8. Guesmi M, Uzan-Augui J, Chopin N, Fayet P, Bienvenu-Perrard M, et al. (2008) Place of MRI in the assessment of cervical cancer. *J Radiol* 89: 1533.
9. Heo SH, Shin SS, Kim JW, Lim HS, Jeong YY, et al. (2013) Pre-Treatment Diffusion-Weighted MR Imaging for Predicting Tumour Recurrence in Uterine Cervical Cancer Treated with Concurrent Chemoradiation: Value of Histogram Analysis of Apparent Diffusion Coefficients. *Korean J Radiol* 14: 616-25.
10. Hori M, Kim T, Murakami T, Imaoka I, Onishi H, et al. (2009) Uterine Cervical Carcinoma: Preoperative Staging with 3.0-T MR Imaging-Comparison with 1.5-T MR Imaging. *Radiology* 251: 96-104.
11. Balleyguier C, Zareski E, Morice P, Lhommé C (2008) Assessment of the extension of cervical cancer by MRI. In: *Syllabus Continuing Medical Education 56th French Days of Radiology, Paris: SFR: 293-6*
12. Delpech Y, Barranger E (2008) Le cancer du col utérin, principes de prise en charge. *Journal de Gynécologie Obstétrique et Biologie de la Reproduction*, 2008 ; 37 (Hors série2) : 51-6.
13. Subak LL, Hricak H, Powell CB, Azizi L, Stern JL (1995) Cervical carcinoma: computed tomography and magnetic resonance imaging for preoperative staging. *Obstet Gynecol* 86: 43-50.
14. Faye N, Coulon A, Beurrier F, Fournier L (2017) FIGO et cancer du col: l'enigme des paramètres. *Journal de Radiologie Diagnostique et Interventionnelle* 98: 71-82.
15. Stenstedt K, Hellstrom AC, Fridsten S, Blomqvist L (2011) Impact of MRI in the management and staging of cancer of the uterine cervix. *Acta Oncologica* 50: 420-6.
16. Sahdev A, Sohaib SA, Wenaden AET, Shepherd JH, Reznik RH (2007) The performance of magnetic resonance imaging in early cervical carcinoma: a long-term experience. *Int J Gynecol Cancer* 17: 629-36.
17. Lam WW, So NM, Yang WT, Metreweli C (2000) Detection of parametrial invasion in cervical carcinoma: role of short tau inversion recovery sequence. *Clin Radiol* 55: 702-7.
18. Rockall AG, Ghosh S, Alexander-Sefre F, Babar S, Younis MTS, et al. (2006) Can MRI rule out bladder and rectal invasion in cervical cancer to help select patients for limited EUA? *Gynecol Oncol* 101: 244-9.
19. Wiebe E, Denny L, Thomas G (2012) Cancer of the cervix uteri. *Int J Gynecol Obstet* 119S2: S100-9.
20. Bhatla N, Berek JS, Fredes, MC, Denny LA, Grenman S, et al. (2019) Revised FIGO staging for carcinoma of the cervix uteri. *Int J Gynaecol Obstet* 145: 129-35.
21. Chung HH, Kang S-B, Cho JY, Kim JW, Park N-H, et al. (2007) Can preoperative MRI accurately evaluate nodal and parametrial invasion in early stage cervical cancer? *Jpn J Clin Oncol* 37: 370-5.
22. Lin WC, Hung YC, Yeh LS, Kao CH, Yen RF, et al. (2003) Usefulness of (18)F-fluorodeoxyglucose positron emission tomography to detect para-aortic lymph nodal metastasis in advanced cervical cancer with negative tomography findings. *Gynecol Oncol* 89: 73-6.
23. Lee SI, Atri M (2019) FIGO Staging System for Uterine

Cervical Cancer: Enter Cross-Sectional Imaging. *Radiology* 292: 15-24.

24. Hertel H, Köhler C, Elhawary T, Michels W, Possover M, et al. (2002) Laparoscopic staging compared with imaging techniques in the staging of advanced cervical cancer. *Gynecol Oncol* 87: 46–51.

25. Ramirez PT, Jhingran A, Macapinlac HA, Euscher ED, Munsell MF, et al. (2011) Laparoscopic extraperitoneal para-aortic lymphadenectomy in locally advanced cervical cancer: a prospective correlation of surgical findings with positron emission tomography/computed tomography findings. *Cancer* 117: 1928–34.

26. Cannistra SA, Niloff JM (1996) Cancer of the uterine cervix. *N Engl J Med* 334: 1030-8

27. Balleyguier C, Kolesnikov-Gauthier H, Haie-Meder C (2014) Post-therapeutic aspect of cervical cancer. In: Bléry M. *Post-therapeutic imaging in oncology*. Elsevier Masson: 205-17.

28. Taieb S, Fauquet I, Gauthier H, Narducci F, Castelan B, et al. (2007) Diagnosis, extension assessment and follow-up of cervical cancer: MRI and only MRI? In: *Continuing Medical Education Syllabus 55th- French Radiology Days, Paris: SFR* 315-22.

29. Balleyguier C, Kinkel K, Haie-Meder C, Morice P, Lhommé C, et al. (2004) What exams should be proposed for the extension assessment and monitoring of cervical cancer: MRI, Scanner, PET-CT? In: *Syllabus Continuing Medical Education 52th French Days of Radiology, Paris: SFR* 43-50.

30. Balleyguier C, Taieb S, Zareski E, Canale E, Uzan C, et al. (2014) Cervical cancer. In: Boudghène F. *MRI of male and female pelvis*. Paris: Springer-Verlag 177-90.

**Submit your manuscript to a JScholar journal and benefit from:**

- ¶ Convenient online submission
- ¶ Rigorous peer review
- ¶ Immediate publication on acceptance
- ¶ Open access: articles freely available online
- ¶ High visibility within the field
- ¶ Better discount for your subsequent articles

Submit your manuscript at  
<http://www.jscholaronline.org/submit-manuscript.php>