

Primary Omental Ectopic Pregnancy: A Rare Disease Not to be Missed

Beng Kwang Ng^{1,*}, Pei Shan Lim¹, Geok Chin Tan², Abdul Kadir Abdul Karim¹, Nurul Zaireen Mohd Uha² and Zainul Rashid Mohd Razi¹

¹Department of Obstetrics and Gynaecology, Universiti Kebangsaan Malaysia Medical Centre, Jalan Yaacob Latif, Cheras, 56000 Kuala Lumpur, Malaysia

²Department of Pathology, Universiti Kebangsaan Malaysia Medical Centre, Jalan Yaacob Latif, Cheras, 56000 Kuala Lumpur, Malaysia

*Corresponding author: Beng Kwang Ng, Department of Obstetrics & Gynaecology, Universiti Kebangsaan Malaysia Medical Centre, Jalan Yaacob Latif, Cheras, 56000 Kuala Lumpur, Malaysia; Tel: +603-91455949; Fax: +603-91456672; Email: nbk_9955@yahoo.com

Received Date: February 07, 2014 Accepted Date: February 23, 2014 Published Date: February 25, 2014

Citation: Ng BK, et al. (2014) Primary Omental Ectopic Pregnancy: a Rare Disease Not to be Missed. J Womens Health Gynecol 1: 1-3.

Abstract

Omental pregnancy is the least common form of abdominal pregnancy. We present a rare case of primary omental pregnancy where patient presented with typical clinical feature of ectopic pregnancy. Trans-vaginal scan revealed an empty uterus with presence of adnexal mass. Fetal echo and fetal heart activity were seen within the mass. However, bilateral fallopian tubes and ovaries appeared to be normal. Part of the omentum was resected to remove a suspicious looking mass, which turned out to be an omental pregnancy.

Keywords: Abdominal pregnancy; Omental pregnancy; Laparoscopy; Laparotomy; Partial omentectomy

Introduction

Abdominal pregnancy is a rare entity but potentially life threatening. The reported incidence was between 1 in 4857 to 7931 [1,2] while omental pregnancy is the least common type. To date, there were only few cases being reported. We report a case of primary omental ectopic pregnancy based on the Studdiford's criteria [3]. In this case presentation, we illustrated the importance of examining the entire abdominal cavity including the omentum particularly when clinical findings are highly suggestive of ectopic pregnancy but both adnexa appeared to be normal at diagnostic laparoscopy.

Case report

A 30-year-old Gravida 4 Para 2+1 presented at eight weeks and five days Period of Amenorrhoea (POA), with sudden onset of lower abdominal pain for one day. She did not have vaginal bleeding or history of passing out product of conception. She had two full term spontaneous vaginal deliveries and one complete miscarriage at seven weeks POA. She had laparoscopic cholecystectomy a year ago. Otherwise, there was no other significant history.

Upon arrival, she was not pale. Her blood pressure was 126/72 mmHg and pulse rate was 88 beats /minute. Abdominal examination revealed tenderness over supra-pubic region with rebound tenderness but no guarding. Upon bimanual examination, the uterus was anteverted, normal size and mobile. There was positive cervical excitation and both adnexae were tender. Bogginess was felt at the Pouch of Douglas (POD).

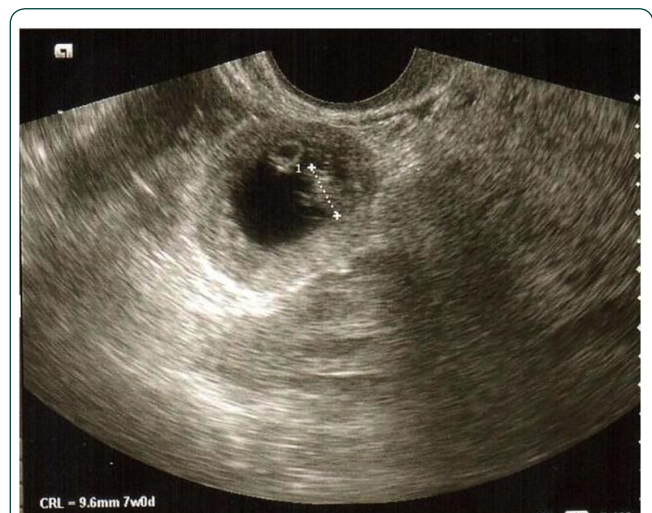

Figure 1: Trans-vaginal scan revealed an extra-uterine gestational sac with fetal echo and fetal heart activity seen.

Trans-vaginal scan revealed an empty uterus with endometrial thickness of 11mm. There was an extra-uterine gestational sac seen with presence of fetal echo and fetal heart activity. The crown lump length measured 9.6mm, which corresponded to seven weeks gestation (Figure. 1). Both ovaries appeared normal. There was presence of free fluid in the POD. Subsequently, she underwent diagnostic laparoscopy for suspected leaking ectopic pregnancy.

Intra-operatively, haemoperitoneum of one litre was noted. Both fallopian tubes and ovaries were normal. The abdominal cavity was examined carefully and a 40x 40 mm-dark suspicious mass, which was actively bleeding, was seen at the momentum (Figure 2).

The procedure was then converted to laparotomy, as there was no immediate expertise available to perform laparoscopic partial omentectomy. Laparotomy partial omentectomy was then performed. The resected omentum was then explored. A fetus in an intact sac was seen within the omental tissue (Figure. 3).

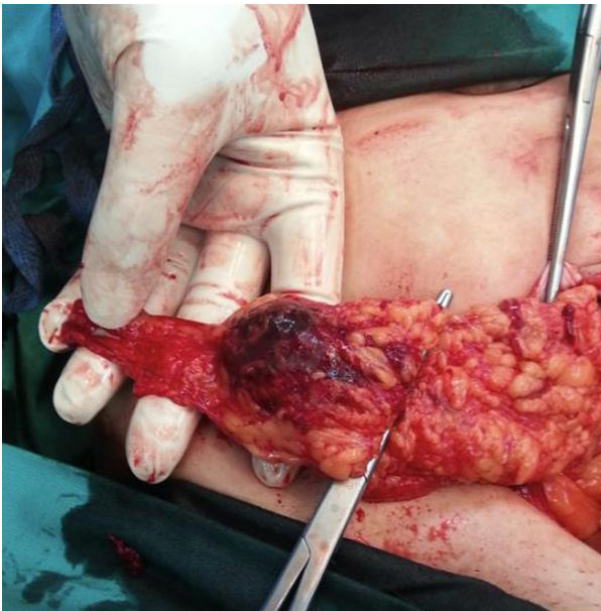


Figure 2: Suspicious omental mass during laparotomy partial omentectomy

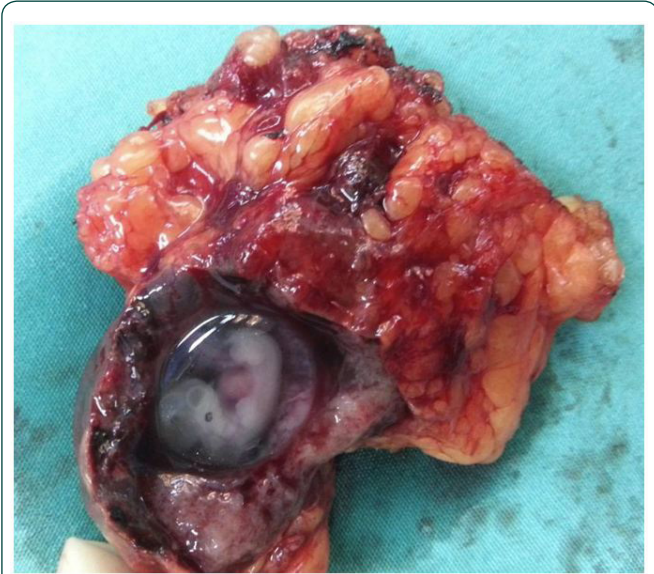

Figure 3: Omental pregnancy with fetal pole seen in side the intact sac

Post-operatively, she recovered well without any need for blood transfusion. Histo-pathological examination of the partial omentectomy specimen confirmed the diagnosis of primary omental ectopic pregnancy as the trophoblastic cells invaded into the omental tissue (Figure 4).

Discussion

Abdominal pregnancy can be classified as primary or secondary. The latter is far more common due to re-implantation of a ruptured tubal ectopic pregnancy [4]. The diagnosis of primary omental pregnancy was made in our case as it fulfilled the Studdiford's criteria: 1) both fallopian tubes and ovaries were normal, 2) there was no uteroplacental fistula, and 3) early attachment of ectopic pregnancy to a peritoneal surface that eliminate the possibility of secondary implantation.

Our patient presented as early as eight weeks gestation making the possibility of secondary implantation less likely. Furthermore, this is confirmed histo-pathologically as the trophoblastic cells invaded into the omental tissue. Initial diagnostic laparoscopy failed to demonstrate the ectopic pregnancy in the pelvis. Both the fallopian tubes and ovaries appeared normal.

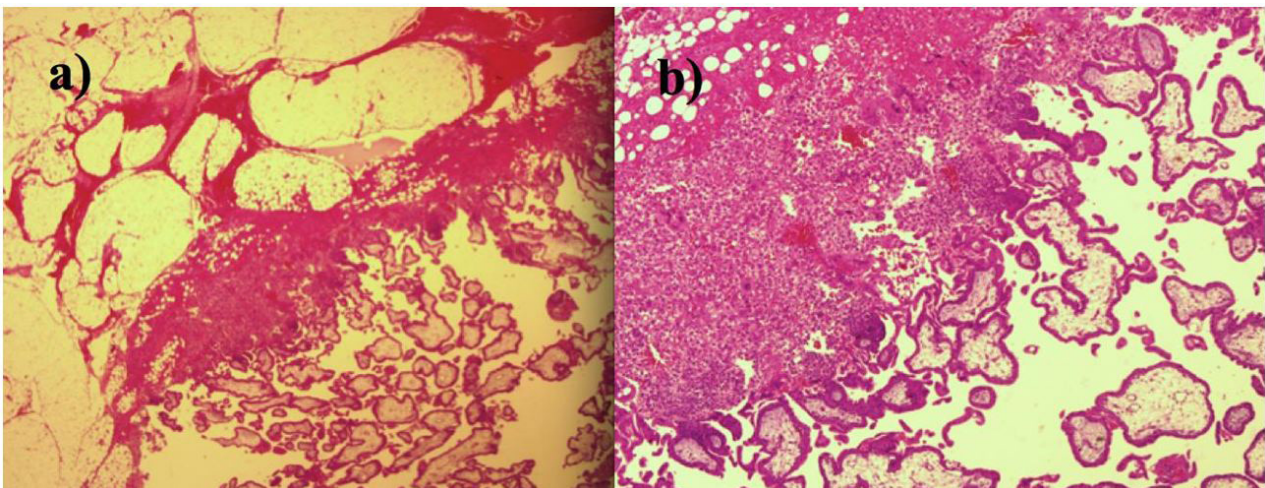


Figure 4: Histo-pathological examination of omental tissue with placental implantation site. a) low magnification showing product of conception with omental tissue; b) high magnification showed trophoblastic cells including syncytiotrophoblast

A suspicious mass was found at the omentum after further exploration.

Diagnosis of primary omental ectopic pregnancy might be missed without extensive surgical evaluation. It was reported that maternal mortality from abdominal pregnancy is 7.7 times higher than tubal ectopic pregnancy and 90 times of a normal intrauterine pregnancy [5]. Its clinical features are not specific; trans-vaginal scan might not always be precise and laparoscopic surgery is rather challenging [3]. It can be easily overlooked and treated as pregnancy of unknown location where catastrophe may occur. We perform further exploration due to the fact that extra-uterine sac with fetal echo and fetal heart activity were seen during ultrasound scan. A normal looking ovaries and fallopian tubes with large amount of haemoperitoneum are highly suspicious of abdominal pregnancy. Wu, et al. [6] reported a 27-year-old woman presented 15 days after methotrexate treatment for persistent ectopic pregnancy post laparoscopic linear salpingotomy. The patient experienced severe abdominal pain and haemorrhagic shock. She underwent laparotomy partial omentectomy and confirmed to have omental pregnancy. Martelli, et al. [7] also reported a similar case of undiagnosed omental pregnancy.

Laparotomy was performed in most of the reported cases [8,9] because of late presentation, severe haemorrhage encountered during laparoscopic surgery or lack of immediate expertise. Laparoscopic surgery for omental pregnancies had been reported especially in early presentation when the sac is not yet ruptured [10,11]. Our case successfully illustrates the importance of having high index of suspicion in managing patients presented with typical clinical features of ectopic pregnancy but no adnexal pathology found during laparoscopy. Thorough assessment of the entire abdominal cavity during laparoscopy is essential to exclude this rare entity of abdominal pregnancy, hence minimising further morbidity and litigation.

References

- 1) Martin JN Jr, Sessums JK, Martin RW, Pryor JA, Morrison JC (1998) Abdominal pregnancy: current concepts of management. *Obstet Gynecol* 71: 549-557.
- 2) Strafford JC, Ragan WD (1997) Abdominal pregnancy: review of current management. *Obstet Gynecol* 50: 548-552.
- 3) Studdiford WE (1942) Primary peritoneal pregnancy. *Am J Obstet Gynecol* 44: 487-491.
- 4) Hallat JG, Grove JA (1985) Abdominal pregnancy: a study of twenty-one consecutive cases. *Am J Obstet Gynecol* 152: 444-449.
- 5) Stovall TG (2002) Early pregnancy loss and ectopic pregnancy. In Berek JS (eds) *Novak's Gynaecology*. Lippincott Williams & Wilkins, Philadelphia.
- 6) Wu MC, Huang WC, Lin HH, Sm Hsiao (2011) Severe intra-abdominal bleeding from neglected omental implantation of ectopic tissue after methotrexate treatment for persistent ectopic pregnancy. *Fertility Sterility* 95: 2435e1-2435e3.
- 7) Martelli F, De Carolis C, Parisi C, Piccione E (2013) Neglected primary omental pregnancy after laparoscopic and medical treatment: a difficult diagnosis? *Case Rep Obstet Gynecol* 2013: 207307.
- 8) Wong WC, Wong PY, Kun KY, Ng TK, Kwok SY, et al. (2004) Primary omental ectopic pregnancy. *J Obstet Gynecol Res* 30: 226-229.
- 9) Ozdemir I, Demirci F, Yucel O, Alper M, et al. (2003) Primary omental pregnancy presenting with hemorrhagic shock. A case report. *Gynecol Obstet Invest* 55: 116-118.
- 10) Onan MA, Turp AB, Saltik A, Akyurek N, Taskiran C, et al. (2005) Primary omental pregnancy: case report. *Hum Reprod* 20: 807-809.
- 11) Esin S, Yildirim H, Tanzer F (2009) Laparoscopic management of a primary omental pregnancy after clomiphene induction. *Fertil Steril* 92: 392e1-392e3.

Submit your manuscript to a JScholar journal and benefit from:

- ¶ Convenient online submission
- ¶ Rigorous peer review
- ¶ Immediate publication on acceptance
- ¶ Open access: articles freely available online
- ¶ High visibility within the field
- ¶ Better discount for your subsequent articles

Submit your manuscript at
<http://www.jscholaronline.org/submit-manuscript.php>