

Double Spinal Arteriovenous Fistula: is this an Acquired Origin?

Ghachem I¹, Bouguila H¹, Hammemi N², Younes S¹

¹Department of Neurologie, Taher sfar Hospital, Mahdia, Tunisia

²Department of Neuroradiology, National Institut of Neurology Mongi BEN HMIDA, Tunis, Tunisia

*Corresponding author: Ghachem I, Department of Neurology, Taher sfar Hospital, Mahdia, Tunisia, Tel: +21694832084, +21652907031, +21673109000, Email: ghachem.ichrak@gmail.com

Received Date: June 15, 2022 Accepted Date: July 28, 2022 Published Date: July 30, 2022

Citation: Ghachem I, Bouguila H, Hammemi N and Younes S (2022) Double Spinal Arteriovenous Fistula: is this an Acquired Origin? J Cardio Vasc Med 8: 1-5.

Abstract

Spinal arteriovenous fistula (SAVF) is a relatively rare entity. Its diagnosis is late due to its variable symptoms. The exact etiology of SAVF is not yet clear. Etiological hypotheses suggest congenital origin with late onset or acquired one.

We report the case of a 64-year-old patient with no notable pathological history. He had a double SAVF. Each one was inaugurated by a distant episode of progressive paraparesis. The 2nd SAVF was diagnosed after 2 years. It was not identified on the 1st arteriography and was located far away from the 1st with different arterial drainage. Would this be in favor of the acquired origin? The patient underwent two embolizations 2 years apart. He had a partial improvement, with a slight paraparesis and dysuria. Our case proves the acquired origin of the 2nd fistula, but does not rule out the hypothesis of the possible congenital origin for the 1st one.

Keywords: Spinal Arteriovenous Fistula, Paraparesis, Etiology, Arteriography, Treatment

Introduction

Spinal arteriovenous fistula (SAVF) is a relatively rare entity, affecting approximately 5 to 10 patients / million / year in the general population in a German series (1). The diagnostic delay is due to the often misleading clinical presentation. The debate on the “congenital, late onset or acquired” origin is still unresolved (2,3).

We report the case of a patient followed in the neurology department of Mahdia for a double SAVF. Each one was inaugurated by a distant episode of progressive paraparesis. The 2nd SAVF was not objectified on the 1st arteriography. Would this be in favor of the acquired origin?

Our objective is to describe the epidemiological and clinico-radiological characteristics of SAVF, their treatments and course. We illustrate through our clinical case this exceptional aspect of double SAVF, to argue the hypothesis of the acquired origin.

Clinical case

Mr. HF, 64 years old, with no notable pathological history, presented a progressive radiculomyelitis over 2 months: heaviness of the right lower limb with progressive worsening of the bone marrow claudication, then bilateralization of the motor deficit and the onset of numbness of the 2 lower limbs more

intense on the right. We noted the presence of genitosphincteric disorders such as dysuria and sexual impotence 2 months before his hospitalization. The neurological examination objectified an ataxic, groping walk more marked on the right, spastic paraparesis predominantly proximally with sharp osteotendinous reflexes, a right Babinski sign, a sensory level D8, error in the sense of the right big toe, and spinal myoclonus of the right limb.

On spinal MRI, he has a serpiginous appearance of the spinal vessels with spinal edema which are in favor of SAVF. He had also a posterior intraspinal T2 hypersignal extended from D3 to L1, a sign of spinal cord ischemia (Figure 1a). Angiography confirmed the presence of epidural C6 to D3 AVF supplied by the right 4th intercostal artery (Figure 1b). Embolization allows complete exclusion of the fistula with clinically favorable outcome. Two years later, he consulted us for a progressive paraparesis predominant this time on the left, osteotendinous reflexes abolished genitosphincter disorders without sensory level. The spinal cord MRI showed a serpiginous appearance of the lumbar vessels, a lumbar hypersignals and a terminal cone hypersignal (Figure 2). Angiography confirmed the complete exclusion of the old fistula (Figure 2a) and the presence of a 2nd dural fistula supplied by a radiculo-meningeal branch of the 1st left lumbar artery (Figure 2b), not seen on the 1st angiogram.

A 2nd embolization was performed successfully. The evolution is marked by an improvement in its symptoms, but partial. He has a slight spastic paraparesis with dysuria. He was put on Liorésal, with regular motor rehabilitation.

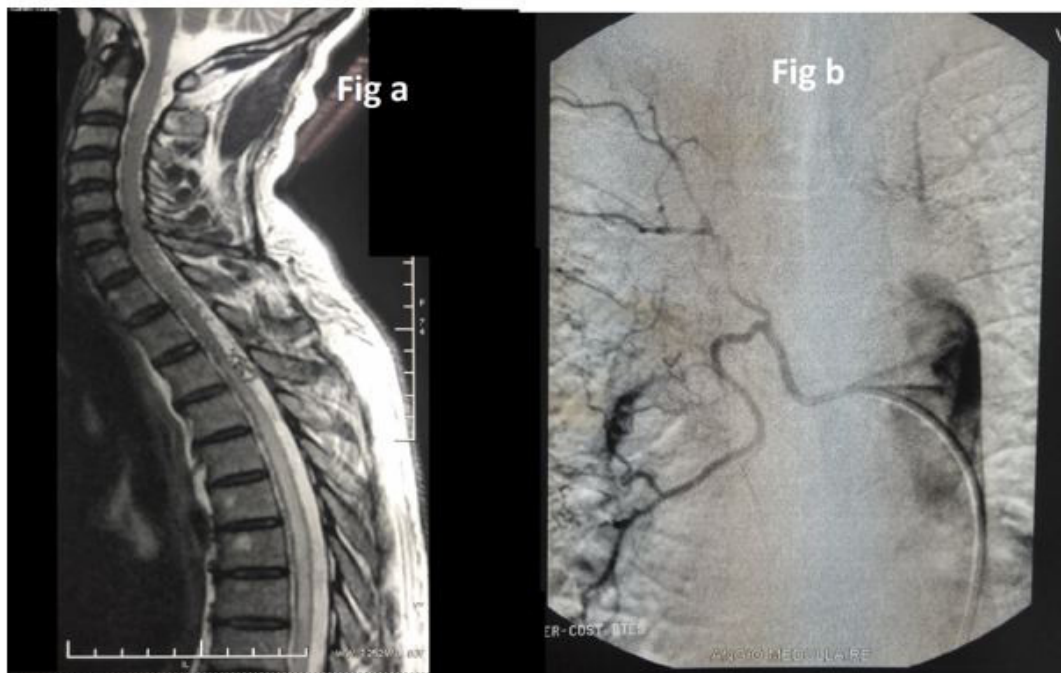


Figure 1: (a) Spinal MRI showed a serpiginous appearance of the spinal vessels with spinal edema which are in favor of SAVF. He had also a posterior intraspinal T2 hypersignal extended from D3 to L1, a sign of spinal cord ischemia. (b) Angiography confirmed the presence of epidural C6 to D3 AVF supplied by the right 4th intercostal artery

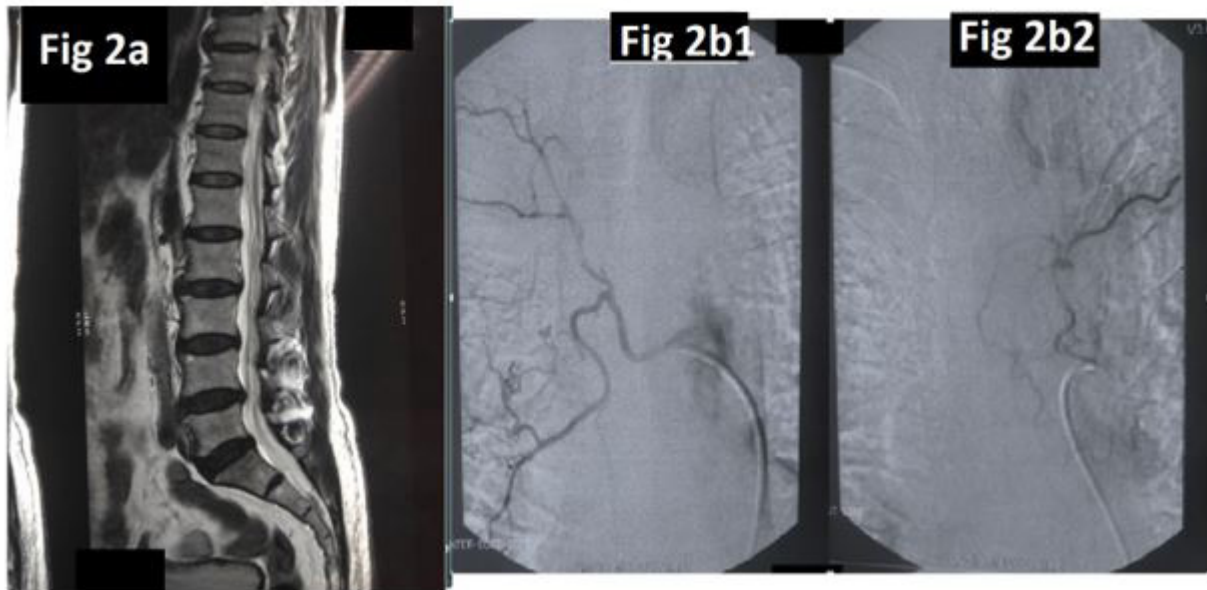


Figure 2: (a) The spinal cord MRI showed a serpiginous appearance of the lumbar vessels, a lumbar hypersignals and a terminal cone hypersignal. (b) Angiography confirmed the complete exclusion of the old fistula (Figure 2b1) and the presence of a 2nd dural fistula supplied by a radiculo-meningeal branch of the 1st left lumbar artery (Figure 2b2), not seen on the 1st angiogram

Discussion

Epidemiology: Spinal vascular malformations are a rare entity, dominated in 70% of cases by SAVF [1]. The age of onset of SAVF is around 50 years old [4]. They are three times more common in men than in women [3,5].

Pathophysiology

Usually, the SAVF is related to the existence of a single shunt between an epidural artery (especially a radiculomeningeal artery such as in our case) and a medullary and / or peri-medullary vein draining against the current [6]. And these, unlike arteriovenous malformations suggesting the existence of a nidus [2].

Impaired tissue perfusion and spinal venous congestion are due to increased peri-spinal venous pressure. This results in chronic ischemic suffering and spinal cord edema [2], explaining the spinal cord ischemia as in our patient. To our knowledge, only one case of double venous drainage has been reported in the literature, but has been discovered on the same angiography [7].

Clinical features

The SAVF are often inaugurated by a progressive myelopathy with motor, sensory and genitosphincteric signs [1,4,7], as noted by the patient. On the other hand, this clinical presenta-

tion is nonspecific and can be polymorphic (6). Initial symptoms may be limited to fatigue or weakness in the lower extremities [1]. Some reported symptoms are misleading, suddenly onset such as a case of syncope [8] and 6 cases suggesting a terminal cone-type spinal cord compression syndrome with even hyperproteinorachia and hypercellularity [9]. Only MRI could rectify the diagnosis. Our patient presented at first a progressive radiculomyelitis. The second episode mimics a terminal cone-type spinal cord compression, where asymmetric paraparesis on the side of the fistula and genitosphincteric disorders predominate.

Other cases have been presented as a cause of failure of lumbar surgery syndrome and should be suspected due to the progressive nature of paraparesis [2].

Spinal Cord Magnetic Resonance Imaging: MRI is a sensitive exam for a positive diagnosis. It shows a specific aspect associating intraspinal edema with dilated peri-spinal vessels [1,2,6].

It individualizes multiple tortuous and serpiginous peri-spinal structures with T2 hypo-signal. They enhance after injection of Gadolinium in connection with vascular peri-spinal structures [1,2]. Sometimes, we can notice some signs of spinal ischemia [2], typically as our case.

Angiography remains the key examination for the diagnosis. It confirms the presence of the shunt with its efferent arteries and its venous return. It is essential for embolization [6,10].

Location and classification

SAVF can occur at any level of the spine [6]. The clinic may steer towards an inaccurate seat higher or lower. This is because of the complex venous drainage pattern, causing venous stasis which spread far from the site of the fistula [3]. SAVF are classified into 4 radiological types: para-spinal, epidural (epidural), dural and intradural SAVF [11,12]. Our patient has 2 types of SAVF: right dural and left epidural fistulas.

Etiology

The exact etiology of SAVF is not yet clear. Some authors suggest that late age of onset argues in favor of an acquired cause [2,3] while others opt for the congenital origin with delayed expression [3].

In our case, the discovery of the 1st fistula at a late age cannot decide between the 2 etiologies. However, the demonstration of a 2nd fistula after 2 years which does not appear on the 1st angiography, the far and contralateral site compared to the 1st, the different type and different arterial drainage, all this argues in favor of the acquired origin of this fistula. We did not find a similar case in the literature, based on our bibliography, which makes our case unique.

Treatment

Most of the reported cases have been treated with embolization with total or partial success [9]. In our case, the 2 embolizations were carried out with success and total exclusion of SAVF. Surgical treatment is indicated if embolization fails. In the event of bleeding, treatment should be postponed 4 to 6 weeks after the bleeding has stopped to ensure spontaneous remission and for safer embolization [11,12].

Evolution and prognosis

The diagnosis of SAVF is often late, explaining the significant functional sequelae [2,4]. The total or partial improvement depends on the early treatment [9]. The gradual disappearance of the initial radiological abnormalities is a sign of the effectiveness of the treatment [6]. Our patient recovered well

after the 1st embolization of the dural fistula. However, he retained moderate motor and genitosphincteric sequelae after the 2nd embolization of the epidural fistula.

The functional prognosis is often linked to the early treatment but no data on the relationship between the type of fistula and prognosis according to our knowledge.

Conclusion

Our case argues in favor of the acquired origin of SAVF. This suggests more study on the risk factors of developing such a fistula. However, the hypothesis of late onset congenital origin remains possible for the 1st fistula in our case. Moreover, knowledge of the epidemiological and clinicoradiological characteristics of SAVF is fundamental for early diagnosis and management. This would prevent serious neurological sequelae.

Acknowledgment

Thank you for all who had contributed to this work.

Conflicts of Interest

We declare No conflicts of interest between authors,

Funding

No source of funding, No ethical issues.

References

1. Ouajdi R, Aichouni N, Mahmoudi L, Mirali H, Belharti A, et al. (2020) Aspect IRM de la fistule artério-veineuse durale médullaire: à propos d'une observation. *Journal of Neuroradiology* 47: 110.
2. Boutahar I, Aichouni N, Zahra Benabdellah F, Oulad Amar, Samba T, et al. (2020) Fistule durale spinale : est-ce grave ? *Journal of Neuroradiology* 47 : 99
3. Korri H, Awada A, Guiziou C, Pougard-Bellec F, Massengo S (2017) Troubles de la marche progressive secondaires à une fistule durale périmédullaire lombaire: à propos d'un cas. *J Med Liban* 65: 58-61.
4. Krings T and Geibprasert S (2009) Spinal Dural Arteriovenous Fistulas. *American Journal of Neuroradiology* 30: 639-648.
5. Lakhdar F, Benzagmout M, Chakour K, Chaoui MF (2019) Traitement chirurgical d'un cas rare de fistule artério-veineuse du filum terminal. *Neurochirurgie* 65: 116-117.
6. Ferchichi A, Boukoucha M, Klaii M, Rbaii L, Ben Khelifa R, et al. (2020) Fistule durale rachidienne. *Journal of Neuroradiology* 47: 132.
7. Xu R, Gregg L, Larry Lo S & Gailloud P (2021) Report of a spinal extradural arteriovenous fistula with double radiculomedullary venous drainage: therapeutic implications and role of intraoperative spinal angiography, *Journal of Neurosurgery: Spine* SPI 34: 799-803.
8. Wan Y, Hurford R, Iorga R. et al. (2021) Posterior fossa dural arteriovenous fistula presenting as 'head-turning syncope': a case report. *Acta Neurol Belg*.
9. Mankai I, Badri M, Bahri K, Rkhami M & Zammel I (2014) Les fistules artérioveineuses durales rachidiennes : à propos de six cas. *Neurochirurgie* 60: 346-347.
10. Wafa Said & Mouna Sghir (2015) La fistule artério-veineuse péri médullaire, une cause rare de paraplégie à ne pas méconnaître. *Pan African Journal* 21: 189.
11. Niang FG, Diop AD, Aidara CM, Deme H, Akpo LG, et al. (2019) Diagnostic IRM et artériographique des fistules artério-veineuses durales médullaires. *Journal Africain d'imagerie* 11: 1
12. Consoli A, Coskun O, Di Maria F, Gratieux J, Auliac S C, et al. (2021) Spinal cord arterio-venous shunts: From classification to therapeutic management, *Revue Neurologique* 177: 469-476

Submit your manuscript to a JScholar journal and benefit from:

- ¶ Convenient online submission
- ¶ Rigorous peer review
- ¶ Immediate publication on acceptance
- ¶ Open access: articles freely available online
- ¶ High visibility within the field
- ¶ Better discount for your subsequent articles

Submit your manuscript at
<http://www.jscholaronline.org/submit-manuscript.php>