

Concomitant Finding of a Large Vessel Vasculitis and a Colorectal Neoplasia on FDG PET/CT

Kargar Samani I*, Krug B, Pirson AS and Vander Borgh T

Department of nuclear medicine, CHU UCL Namur, Godinne site, Université catholique de Louvain, Belgium

*Corresponding author: Kargar Samani I, Nuclear Medicine Department, CHU UCL Namur, Godinne site, Université catholique de Louvain, Dr G. Therasse 1, 5530 YVOIR, Belgium, Tel: +32 81.42.34.00, Fax +32 81.42.34.08, Email: isaac.kargar@gmail.com

Received Date: June 08, 2022 Accepted Date: July 11, 2022 Published Date: July 13, 2022

Citation: Kargar Samani I, Krug B, Pirson AS and Vander Borgh T (2022) Concomitant Finding of a Large Vessel Vasculitis and a Colorectal Neoplasia on FDG PET/CT. J Radiol Nucl Med 2: 1-3

Abstract

A 64-year-old female patient underwent an F-18 fluorodeoxyglucose positron emitting tomography/computed tomography (FDG PET/CT) for evaluation of inflammation not responding to steroid therapy in the setting of suspected polymyalgia rheumatica. A hypermetabolic mass was found at the rectosigmoid junction associated with hypermetabolic hepatic hypodense lesions as well as a hypermetabolic thickening of large vessels' wall (aorta, carotids, subclavian arteries, axillary arteries, iliac arteries and femoral arteries). In this setting, we suspected the vasculitis to be paraneoplastic.

Keywords: Large Vessel Vasculitis, F-18 fluorodeoxyglucose, Paraneoplastic, Cancer

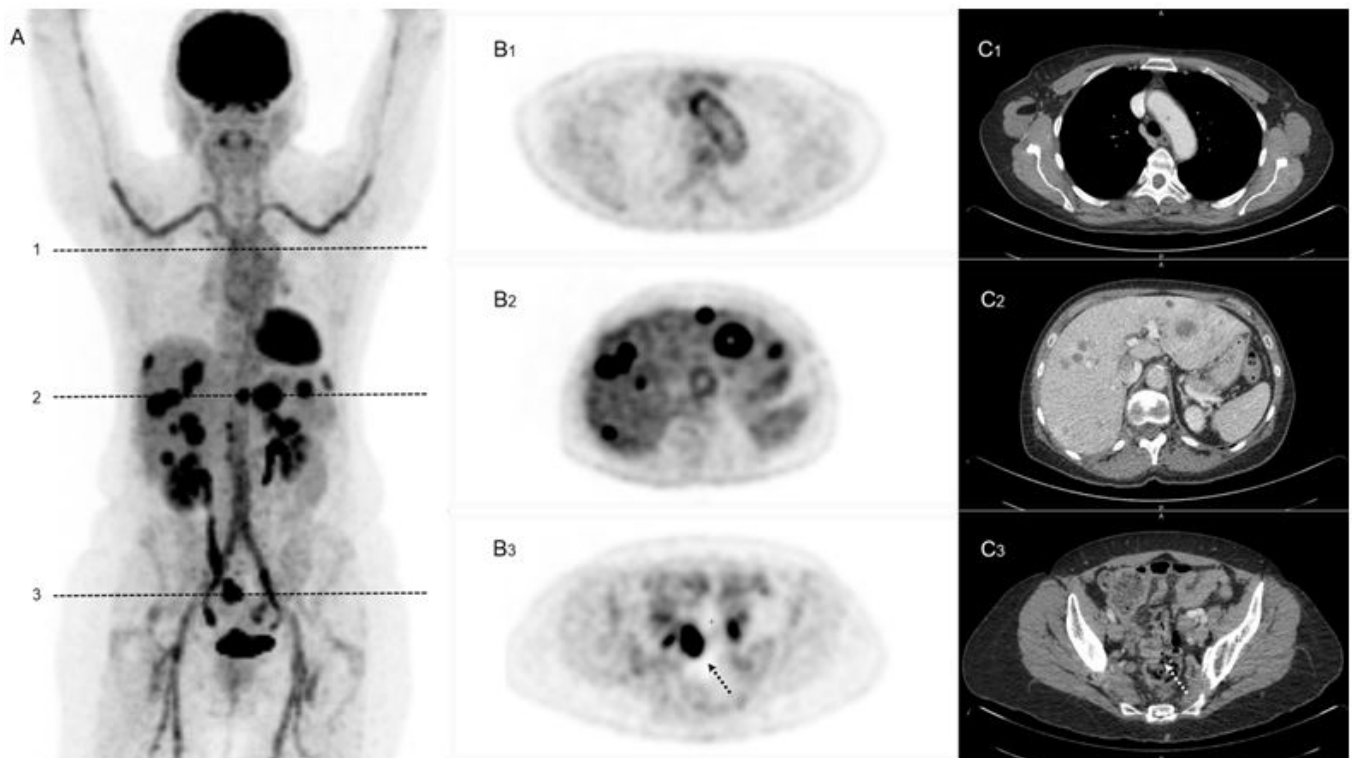


Figure 1: The maximal intensity projection image (A), the PET (B) and enhanced CT (C) slices show hypermetabolic thickening of large vessels' wall (B₁ and C₁), liver metastases (B₂ and C₂) and the tumor (dotted arrows on B₃ and C₃).

Paraneoplastic vasculitis is a rare condition that has not been frequently described mainly because of the difficulty to establish a causal relationship between cancer and vasculitis [1]. They account for 2 to 5% of all vasculitides [1]. They predominantly affect small and medium vessels, the most common vasculitis being leukocytoclastic vasculitis, and seem to be more often related to hematologic neoplasms with a proven association between hairy cell leukemia and polyarteritis nodosa [1,2]. Nonetheless, there have been a few articles reporting associations between large vessels vasculitis and hematologic cancers such as chronic myeloid leukemia [3,4], chronic myelomonocytic leukemia [5] and myelodysplastic syndrome [6] and there was one case report of an aortitis as a paraneoplastic syndrome of a colon adenocarcinoma [7]. Response to treatment appears to be very inconsistent with some patients showing a rapid response to steroid therapy and others relapsing [5,6], some never showing any improvement in the first place and needing specific treatment of the underlying malignancy [7]. In our case, the patient was not showing much response to steroid therapy either, but after initiating chemotherapy, C-reactive protein started declining, going from 102 mg/L to 19 mg/L in a month and dwindling to 5.8 mg/L the following month, which gave weight to the diagnosis of paraneoplastic vasculitis.

Consent

Consent was obtained from the patient.

Author Contributorship

Here you will find the contributions of all co-authors: Isaac Kargar Samani (1,2), Bruno Krug (1,2), Anne-Sophie Pirson (2) and Thierry Vander Borghet (1,2). They are based on the following criteria published in the guide for authors: drafting the article or revising it critically for important intellectual content (1) and final approval of the version to be submitted (2).

Conflict of Interest

The authors have no conflicts of interest to disclose.

References

1. Azar L, Khasnis A (2013) Paraneoplastic Rheumatologic syndromes. *Curr Opin Rheumatol* 25: 44-9.
2. Kermani TA, Warrington KJ, Amin S (2011) Malignancy risk in vasculitis. *Ther Adv Musculoskelet Dis* 3: 55-63.
3. Yuce Inel T, Gulcu A, Karakas A, Erdogan Yucel E, Onen F (2021) Coexistence of Takayasu arteritis and chronic myeloid leukemia: Coincidental or paraneoplastic phenomenon? *Int J Rheum Dis*. 24: 1213-1216.
4. Park JK, Gelber AC, Zheng G, McDevitt MA, Gocke CD, Baer AN (2011) Large-vessel vasculitis as an early manifestation of chronic myelomonocytic leukemia. *J Clin Oncol* 29: e601-603.
5. Sasinowska S, Traisak P, McCormack M, Eid H (2017) A Rare Case of Paraneoplastic Aortitis Associated with Chronic Myelomonocytic Leukemia. *Case Rep Hematol*. 2017: 3091973.
6. Yabe H (2018) Paraneoplastic Large-vessel Vasculitis Associated with Myelodysplastic Syndrome. *Intern Med*. 57: 2769-2771.
7. O'Connell EW, Reams J, Denio AE (2019) Aortitis as a Harbinger of Occult Malignancy. *Case Rep Rheumatol*. 2019: 8385630.

Submit your manuscript to a JScholar journal and benefit from:

- ¶ Convenient online submission
- ¶ Rigorous peer review
- ¶ Immediate publication on acceptance
- ¶ Open access: articles freely available online
- ¶ High visibility within the field
- ¶ Better discount for your subsequent articles

Submit your manuscript at
<http://www.jscholaronline.org/submit-manuscript.php>